



Histopathological lesions of nasal cavity, paranasal sinuses and nasopharynx

Janice Jaison*, Deepa Topandas Tekwani

Department of Pathology, MIMER Medical College, Talegaon (D) Pune, India

Keywords: *Polypoid lesions, nasal cavity, paranasal sinuses, nasopharynx*

Abstract

Background: The parts of the upper respiratory tract included in the present study are- Nasal Cavity, Paranasal sinuses and Nasopharynx. Majority of the lesions at these sites are polypoid. It is difficult to comment upon the nature of the lesion- whether neoplastic or non-neoplastic. Hence histopathological examination is essential for both ENT surgeons as well as pathologists.

Methods: The study involved an analysis of specimens received in the surgical pathology laboratory from the department of ENT over a period 5 years.

Result: A study of 104 lesions was undertaken. They constituted 3.06% of the total histopathological work load at our institution. Inflammatory and tumor like lesions constituted 74.04% followed by malignant tumors constituting 13.46% and benign tumors constituting 12.50% of the total number of cases.

Conclusion: The age group in this study ranged from 7 to 75 years. Inflammatory and tumor like lesions were seen in all age groups, while benign tumors showed a peak incidence in the 1st and 2nd decade and malignant tumors were common in the 4th to 6th decade. Males were more commonly affected by the various lesions as compared to females. Inflammatory and tumor like lesions were the most common lesions occurring at these sites, followed by malignant tumors and benign tumors respectively.

*Corresponding author:

Dr. Janice Jaison, Flat no 2, Jai Apts, Plot no 121, Sect-26, Pradhikaran, Nigdi, Pune-44, India



Introduction

The parts of the upper respiratory tract included in our study are: Nasal cavity, Paranasal sinuses and Nasopharynx. The upper respiratory tract gets exposed to a variety of infections and many other influences in the environment. Due to the effect of these factors, various infections, tumor like lesions and true neoplasms occur in the upper respiratory tract. Fortunately, lesions of the upper respiratory tract though are most common afflictions of humans; the overwhelming majority are more nuisances than threats. The main lesions of this region are inflammations- both acute and chronic. Majority of these lesions of the nose and paranasal sinuses are polypoid. From the clinical examination of the patient or from the macroscopic examination of the specimen it is difficult to comment upon the nature of the lesion-whether neoplastic or non-neoplastic. Hence histopathological examination is essential for both ENT surgeons as well as pathologists.

Materials and Methods

The study involved analysis of specimens received in the surgical pathology laboratory from the Department of ENT over a period of 5 years. The personal details of the patient were noted along with the presenting complaints. A detailed clinical examination with special reference to ear, nose and throat examination was performed. Routine blood investigations were done in all patients and radiological investigations like X-ray, CT Scan and MRI were also done wherever relevant. A Final diagnosis was offered after Histopathological examination. The specimens received and studied were the result of the following operative procedures

1. Nose – Excision biopsy, polypectomy
2. Paranasal Sinuses- Ethmoidectomy: Caldwell-Luc operation, Total Maxillectomy/Extended maxillectomy/lateral Rhinotomy/neck dissection
3. Nasopharynx- Adenoidectomy

All of the above specimens on being received in the surgical pathology laboratory were fixed in 10% formalin overnight and a detailed gross examination was done the subsequent day. All tissues submitted were processed according to routine histological techniques and paraffin sections were obtained. All sections were stained by haematoxylin and eosin (H&E) method and examined microscopically.

Special stains were performed wherever necessary. These included- Reticulin, Mucicarmine, PAS, Acid fast stain, Grocott's methanamine silver and Giemsa

Result

The present study includes the lesions of the nasal cavity, paranasal sinuses and nasopharynx. These lesions were studied over a period of five years. During the course of this study, a total of 3393 specimens were received in the surgical pathology department. Of these, 104(3.06%) constituted the specimens of nose, paranasal sinuses and nasopharynx (Fig 1). The lesions were grouped into 3 categories: Inflammatory and tumor like, benign tumors and malignant tumors. Inflammatory and tumor like lesions were the commonest constituting 74.04% of the total cases, followed by malignant tumors constituting 13.46% and benign tumor constituting 12.5% of the cases (Fig. 2).

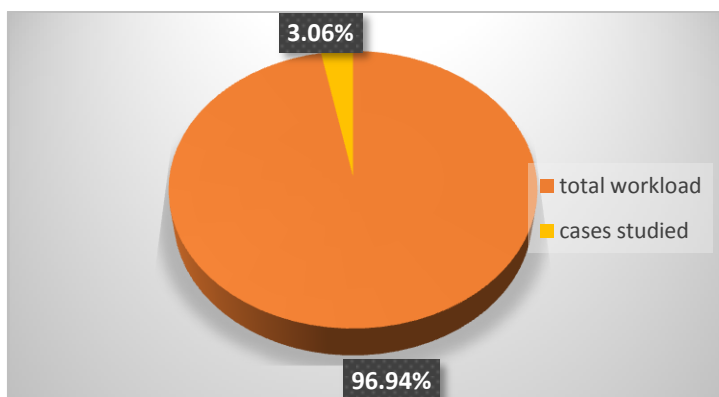


Fig 1- Comparison of cases studied with the total workload of surgical pathology department

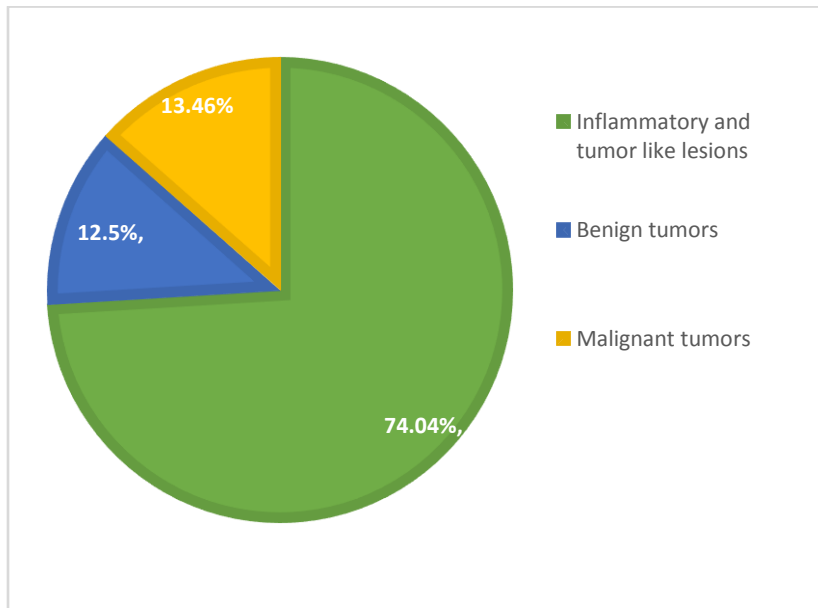


Fig 2: Comparison between % of inflammatory and tumor like lesions, Benign and Malignant tumors

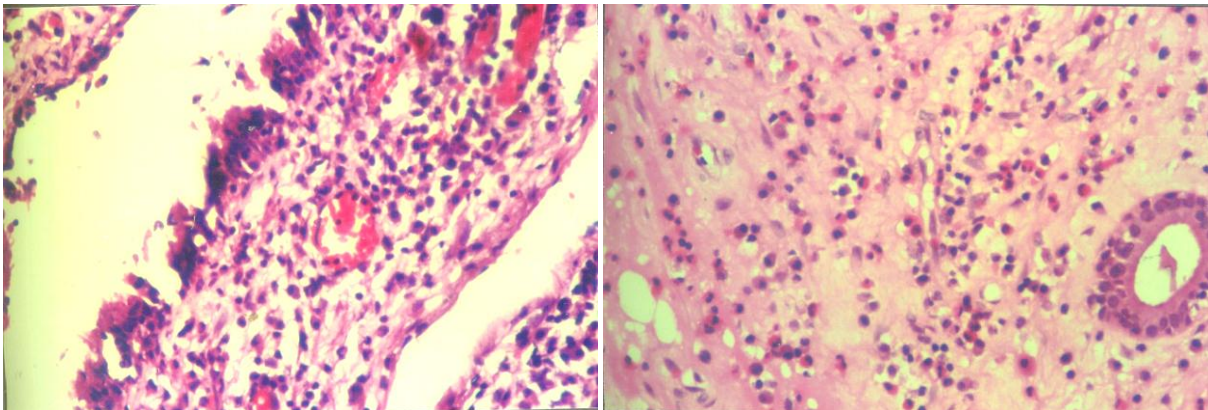


Fig 3: Photomicrograph of Inflammatory polyp, showing lining respiratory epithelium beneath which is seen a predominantly lymphocytic inflammatory infiltrate with a few plasma cells and neutrophils (H& E, X 40)

Fig 4: Photomicrograph of Allergic polyp showing a predominantly eosinophilic inflammatory infiltrate with a few plasma cells and lymphocytes. (H&E, X40)

In the inflammatory and tumor like conditions, Inflammatory polyps were the commonest lesions. Out of the 77 cases of inflammatory and tumor like lesions, there were 28 cases of Inflammatory polyps constituting 26.93%. This was followed by Allergic polyps, of which there were 22 cases (21.16%), 14 cases of Rhinoscleroma (13.46%), 4 cases of Rhinosporidiosis (3.85%), 3 cases of Atrophic Rhinitis (2.89%) and 2 cases each of Rhinophyma, cholesterol granuloma and Adenoids (1.92% each). (Fig.3-7)

Out of the total of 104 cases, there were 13 cases of benign tumors. There were 5 cases each of Nasopharyngeal angiofibroma and Inverted Papilloma constituting 4.81% each followed by 3 cases of Capillary haemangioma constituting 2.88%. (Fig 8-9) 14 malignant tumors were studied. Well differentiated squamous cell carcinoma of the maxillary sinus was the commonest lesion in this group. There were 4 cases constituting 3.85% followed by 2 cases each of Adenoid cystic carcinoma, Olfactory neuroblastoma and Well differentiated squamous cell carcinoma of nasopharynx. (1.92% each). (Fig 10)

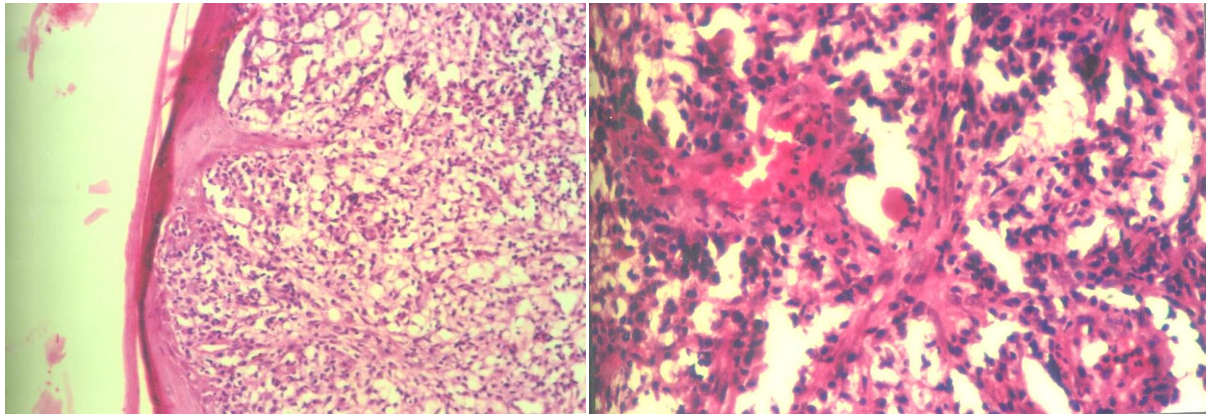


Fig 5: Photomicrograph of Rhinoscleroma showing stratified squamous epithelium, beneath which are seen plenty of foamy macrophages. (H&E,X4)

Fig 6: Photomicrograph of Rhinoscleroma showing a naked eosinophilic hyaline mass- Russell body seen in a background of chronic inflammatory cells (H&E,X40)

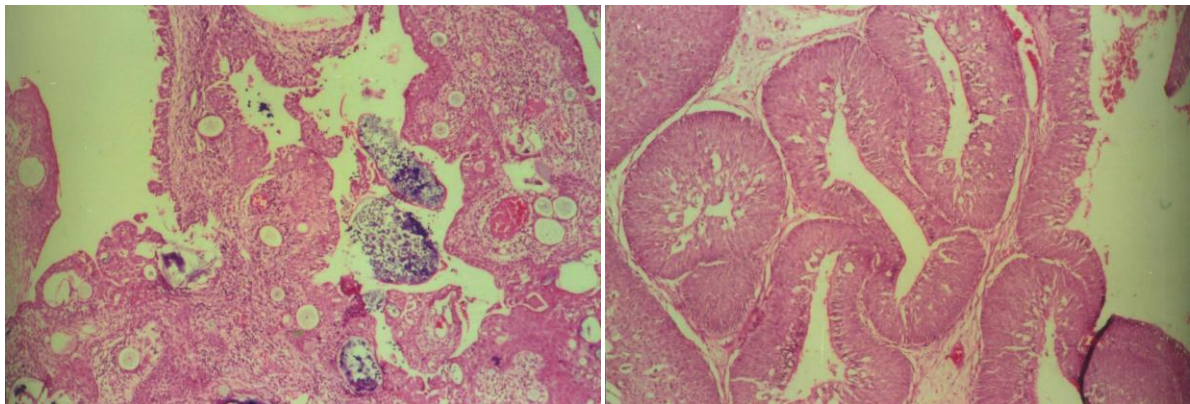


Fig 7: Photomicrograph of Rhinosporidiosis showing an ulcerated respiratory epithelium. Beneath is seen a vascular inflammatory granulation tissue, containing sporangia in varying stages of maturity enclosing spores(H&E, X4)

Fig 8: Photomicrograph of Inverted Papilloma showing epithelial proliferation accommodated by infolding into the edematous stroma (H&E,X10)

The remaining malignant lesions were Poorly differentiated carcinoma of nose, Mesenchymal chondrosarcoma and Well differentiated carcinoma of ethmoidal sinus of which single cases were studied (0.96% each). (Table 1) Inflammatory and tumor like lesions were common in the 1st to 3rd decade, benign tumors were commonest in the 1st and 2nd decade, while malignant tumors were common in the 4th to 6th decade. Inflammatory and tumor like lesions and benign tumors were more common in males, while malignant tumors were common in females.

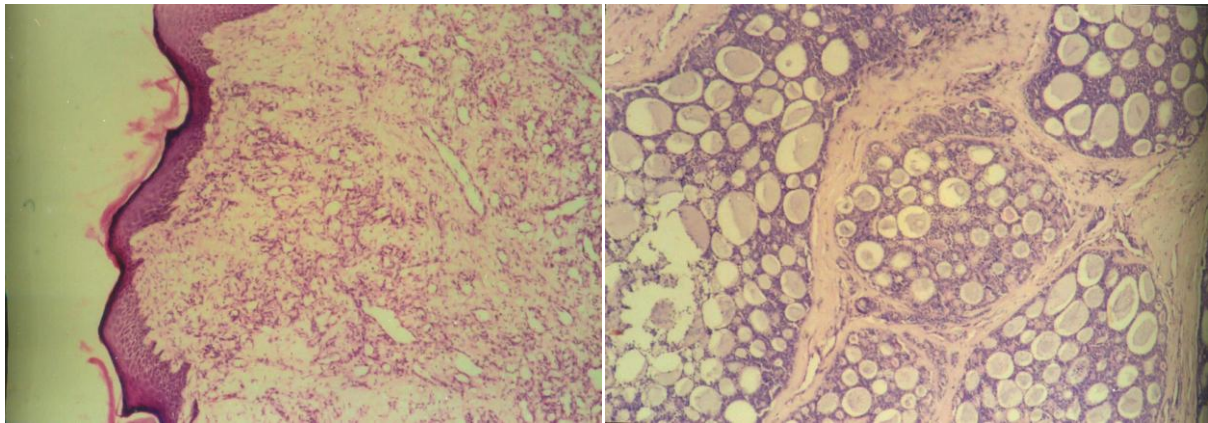


Fig 9: Photomicrograph of Juvenile Nasopharyngeal Angiofibroma showing stratified squamous epithelium beneath which are seen plenty of capillary sized blood vessels. (H&E, X4)

Fig 10: Photomicrograph of Adenoid Cystic Carcinoma showing classical cribriform pattern (H&E, X10)

Table 1. Incidence of various lesions

Lesions	Number of cases	% of cases
Allergic polyp	22	21.16
Inflammatory polyp	28	26.93
Rhinoscleroma	14	13.46
Rhinosporidiosis	4	3.85
Rhinophyma	2	1.92
Atrophic Rhinitis	3	2.89
Cholesterol Granuloma	2	1.92
Adenoids	2	1.92
Nasopharyngeal angiofibroma	5	4.81
Inverted Papilloma	5	4.81
Capillary Haemangioma	3	2.88
Poorly differentiated Ca of nose	1	0.96
Adenoid Cystic Ca of ethmoidal sinus	2	1.92
Adenoid Cystic Ca of maxillary sinus	1	0.96
Well differentiated SCC of maxillary sinus	4	3.85
Well differentiated SCC of ethmoidal sinus	1	0.96
Mesenchymal Chondrosarcoma	1	0.96
Olfactory neuroblastoma	2	1.92
Well differentiated SCC of nasopharynx	2	1.92

Discussion

The present study of histopathology of lesions of the nasal cavity, paranasal sinus and nasopharynx included 104 lesions encountered over a period of 5 years.

Out of these 104 cases, 27 cases were Neoplastic (25.96%) and 77 (74.04%) were inflammatory and tumor like lesions. Of the neoplastic lesions 13(48.15%) were benign and 14 (51.85%) were malignant tumors. This is in agreement with Ash¹, Buchanan and Salvin², Ghosh and Bhattacharya³. But Tandon⁴ reported incidence of benign tumors as 73.3% and malignant tumors as 26.5% in their study.

In the present study the ratio of benign to malignant tumors in the nose was 1.3:1 and in the paranasal sinuses, only malignant tumors were found. This is in accordance with Friedman and Osborn⁵ who found the ratio of be-

nign to malignant tumors in the nasal cavity about 6:1, while in the paranasal sinuses the ratio was reverse, there being and increase in the number of malignant tumors.

Rhinoscleroma: in the present study there were 14 cases of Rhinoscleroma. There was a male predoinance with male to female ratio of 6: 1, which is in agreement with Kakar and Sinha⁶. . No particular age group predominance was seen. Rhinoscleroma was common in the 1st to 4th decade. The findings of the present study coincide with studies carried out by Kakar and Sinha⁶. All the patients were from poor socio-economic strata.

Rhinosporidiosis: in the present study, there were four cases of Rhinosporidiosis. All of them were male patients. Many Indian workers- Ratnakar⁷, Makannavar⁸ and Ahluwalia H⁹ have reported cases of rhinosporidiosis collected over years. Rhinosporidiosis is commonly encountered in the 1st to 3rd decade. In our study, out of the 4 cases, 2 cases were encountered in the 3rd to 4th decade, 1 case in the 2nd to 3rd decade and 1 case in the 4th to 5th decade. All the 4 cases studied occurred in male patients, which corresponds to the studies carried out by various Indian authors indicating that males are predominantly affected in Rhinosporidiosis.

Nasal Polyps: These were the commonest lesions found in our study of 104 cases. Out of 77 non neoplastic lesions included in our study, 50 cases were of inflammatory and allergic polyp. Antrochoanal polyps mainly presented in the second and third decade but no such age distribution was observed in ethmoidal polyps. Female predominance was seen in our series of cases. The incidence of nasal polyps in our studies corresponds to the incidence of nasal polyps in studies carried out by Tandon⁴. Allergic polyps were common as compared to inflammatory polyps in studies carried out by Tandon⁴. In our study, however, inflammatory polyps were common as compared to allergic polyps and constituted 56%.

Atrophic Rhinitis: Three cases of atrophic rhinitis were studied. 2 cases in females and 1 in a male patient. The epithelial changes varied from partial squamous metaplasia to total squamous metaplasia with keratinization. The lamina propria showed chronic inflammatory infiltrate, granulation tissue and fibrosis. These findings correspond to the earlier studies carried out by Anand and Agarwal¹⁰, Sinha¹¹ and Ishwar Singh¹².

Cholesterol Granuloma: 2 cases of cholesterol granuloma were recorded. These were similar to the cholesterol granuloma of the middle ear. They are said to occur as a result of extensive degeneration within an inflammatory polyp.

Rhinophyma: 2 cases of rhinophyma were studied. They showed classical histological features of hyperkeratosis of the epidermis and hypertrophy and hyperplasia of sebaceous glands.

Adenoids: 2 male patients presented with nasal obstruction and difficulty in breathing due to enlarged adenoids.

Benign lesions

Nasopharyngeal angiofibroma: in the present study, there were 5 cases of angiofibroma. Of the 5 cases, 4 cases were males and one case was a female. The age group was 1st and 2nd decade of life. This is in agreement with English¹³ and Biller¹⁴.

Inverted Papilloma: in the present study, there were 5 cases of inverted papilloma, 4 male patients and one female. Male predominance was seen in our study with majority of cases occurring in the 5th to 6th decade. This is in accordance with studies carried out by Lawson and Billen.¹⁵

Capillary Haemangioma: in the present study, there were 3 cases of capillary haemangioma. All of the 3 cases were male patients. All patients presented with epistaxis and nasal obstruction.

Malignant lesions

In the present study of 104 cases, there were 14 cases of malignant neoplasms. Out of the 14 cases, 2 cases were malignancies of nasopharynx, 8 cases of malignancies of paranasal sinuses and 4 cases of malignancies of the nasal cavity. Maxillary sinus was most commonly involved (35.71%). This is in comparison with Frazell and Lewis¹⁶ Acheson¹⁷, Lewis and Castro¹⁸ and Wang¹⁹

In the present study, squamous cell carcinoma was the commonest of the malignant tumors encountered in the paranasal sinuses comprising 62.5%.

Conclusion

The age group in this study ranged from 7 years to 75 years. For benign tumors peak incidence was in the 1st and 2nd decade and for the malignant tumors in the 4th to 6th decade of life. In tumor like and inflammatory lesions male to female ratio was 1.2 :1, while in neoplastic cases, males were affected more as compared to females and ratio of male to female cases was 1.07: 1.

In the tumor like and inflammatory lesions simple nasal polyps were the commonest (64.93%). Inflammatory nasal polyps were common as compared to allergic nasal polyps and constituted 56%. The malignant tumors (51.85%) were common as compared to the benign lesions (48.15%). The maxillary sinus was commonly affected (35.71%) in all malignant neoplasms. The most common histological type of malignancy encountered was squamous cell carcinoma (57.14%).

As most of the lesions of nasal cavity, paranasal sinus and nasopharynx can present as polyp like lesions, their histopathological examination can help the surgeons in diagnosis of a disease and choosing the right modality of treatment for the patient.

Acknowledgements

My most heartfelt and sincere gratitude to my guide Brig. (Dr) S. K. Basu, for his steadfast yet patient guidance without which this study would never have been completed. My sincere thanks to Dr. Neeta Kulkarni, who provided me with the clinical material and subsequent exchange of notes. I am grateful to Dr. Smita Pathak, for the invaluable assistance graciously rendered to me during this study.

Funding

None.

Competing Interests

None declared.

References

1. Ash J. E., Beck M. R., Wilkes J. D., Tumors of the upper respiratory tract and ear in Atlas of Tumor Pathology, 1964; Section IV, Fascicles 12,13 Armed Forces Institute of Pathology, Washington D.C.
2. Buchanan G and Salvin G, Tumors of nose and paranasal sinuses. A clinicopathological study. *Journal Laryngol Otol* 1972; 86:685
3. Ghosh A and Bhattacharya K., The nasal and nasopharyngeal growths. A 10 years study. *Journal Indian Med. Assoc.* 1966; 47:14
4. Tondon P. L., Gulati J. and Mehta N., Histopathological study of polypoidal lesions in the nasal cavity. *Indian Journal of Otolaryngol*, 1971; 13:3
5. Friedman I, Osborn DA. Pathology of Granulomas and Neoplasms of the Nose and Paranasal Sinuses. Churchill Livingstone, Edinburgh London Melbourne and New York 1982
6. Kakar P., Sinha A., The problems of scleroma in India. *Indian Journal of Otolaryngol*, 1964; 16:164
7. C Ratnakar, M Madhavan, Vanaja Sankaran, Andrew J Veliath, N K Majumdaar, Vasudev Anand Rao. Rhinosporidiosis in Pondicherry. *Journal of Tropical Medicine and Hygiene*, 1992; 95 (4):280-283.
8. J. H. Makannavar, S. Sateesh Chavan: Rhinosporidiosis- A clinicopathological study of 34 cases. *Indian J Pathol Microbiol* 2001; 44:17-21
9. Ahluwalia H. K. B., New interpretation of Rhinosporidiosis. *J Submicrosc Cytol Pathol.* 1992; 24: 109-11
10. Anand CS, Agarwal SR. A histopathological study in Atrophic Rhinitis. *JIMA*, 1972; 59:278-281
11. Sinha S. N., Samuel K.C., Juneja H.S., Mittal D.P: A study of exfoliative cytology of atrophic rhinitis. *J Laryngol Otol*, 1975; 89:1027-1041
12. Ishwar Singh, R. M. Raizada, V. N. Chaturvedi, S. K. T. Jain, S.N. Ingole Study of histopathological changes in Atrophic Rhinitis, *Indian Journal of Otolaryngology and Head & Neck Surgery*, 1999; Vol 51, No.1: 21-24
13. English GM, Hemenway WG, Cundy RL: Surgical treatment of angiofibroma. *Arch Otolaryngol*, 1972; 96:312
14. Biller HF, Session OG, Ogura JH: Angiofibroma- A treatment approach. *Laryngoscope*, 84; 695-705
15. Lawson W, Billen H. F., Jacobson A, Som P, The role of conservative surgery in the management of inverted papilloma. *Laryngoscope*, 1983 (2); 93:148-155.
16. Frazell EL, Lewis JJ: Cancer of nasal cavity and accessory sinuses. Report of management of 416 patients. *Cancer*, 1963; 16:1263
17. Acheson E. D., Cowdell R. H., Jolles B., Nasal cancer in the Northampshire Boot and Shoe Industry. *Br. Med. Journal* 1970; 1: 385-93
18. Lewis J. S., Castro E. B., Cancer of the nasal cavity and paranasal sinuses. *J Laryngol Otol*, 1972; 86: 255-262
19. Cheng VST, Wang CC: Carcinoma of the paranasal sinuses. A study of 66 cases. *Cancer*, 1977; 40 (6):3038-3041.