



## Case Report

# Central Serous Chorioretinopathy Leading to sub Retinal Bleed to Postvitrectomy Endophthalmitis: Diagnostic Dilemma

Balbir Khan<sup>1</sup>, Vartika Anand<sup>1\*</sup>, Sachin Anand<sup>2</sup> and Meenu Kashyap<sup>1</sup>

<sup>1</sup>Adesh Medical College and Hospital Mohri NH 1 Ambala, India

<sup>2</sup>Shri Har Rai Shaib Diagnostic Centre, Sector 22 D, Chandigarh, India

**Keywords:** Endophthalmitis, Subretinal Haemorrhage, Central Serous Retinopathy

### ABSTRACT

Central serous retinopathy (CSR) is a common cause of visual disturbance in the younger age group. Spontaneous visual recovery occurs in the majority of patients. A minority of patients, however, suffer permanent visual loss commonly caused by chronic retinal pigment epithelial changes. We report a devastating complication of CSR, with sub retinal haemorrhage.

**\*Corresponding author:**

Dr. Vartika Anand, House NO.169 Sector 19-A Chandigarh 160019, India.

Phone: +91 9988880755

E-mail: varti\_in@yahoo.com

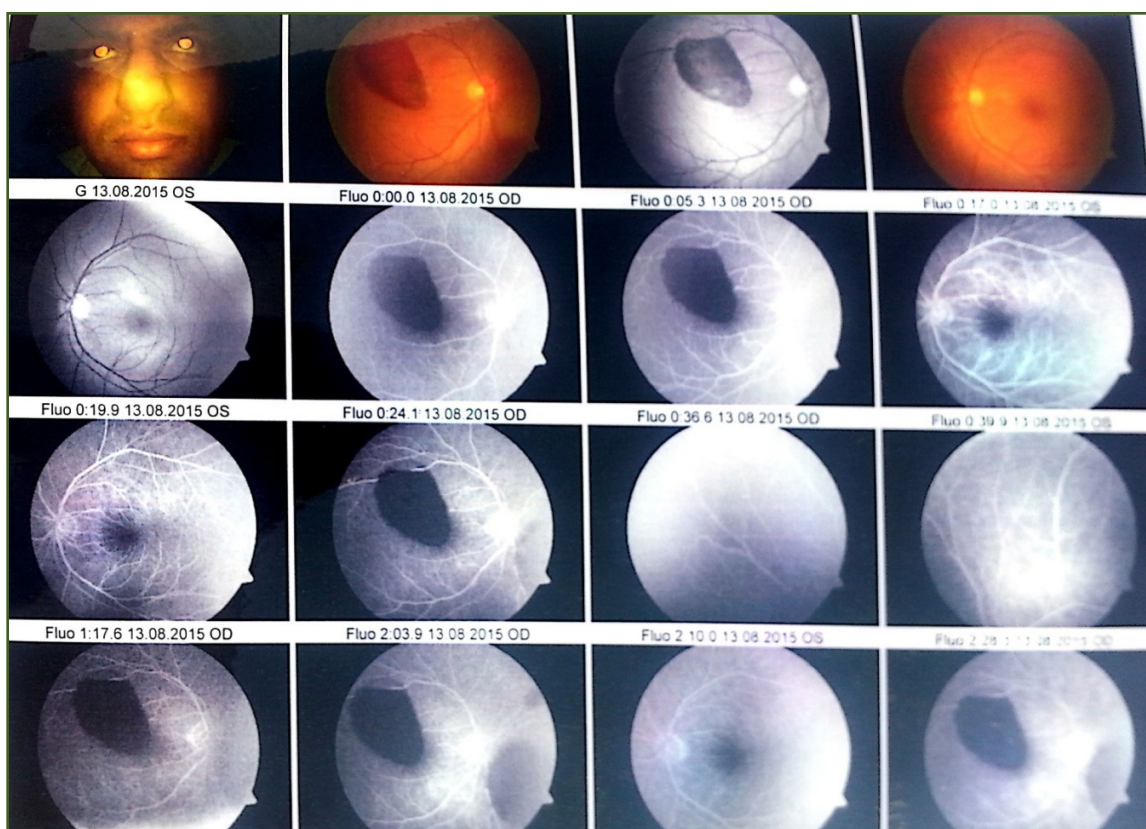
## Introduction

Central serous chorioretinopathy (CSCR) is a disease in which a serous detachment of the neurosensory retina occurs over an area of leakage from the choriocapillaris through the retinal pigment epithelium (RPE). Other causes for RPE leaks, such as choroidal neovascularization, inflammation, or tumors, should be ruled out to make the diagnosis.

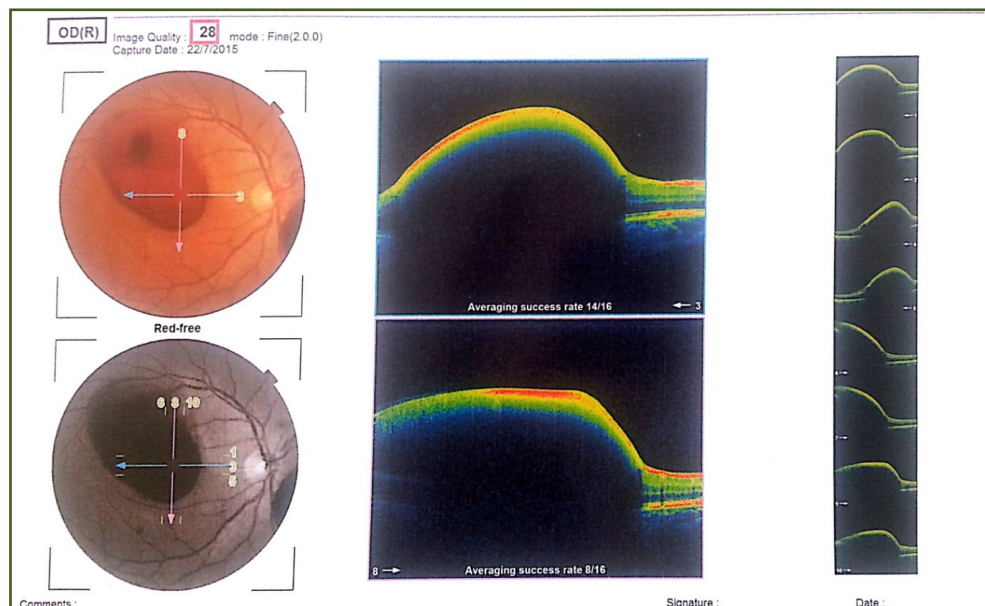
## Case Report

A 34 year old young male presented with a 2 week history of blurred central vision and metamorphopsia affecting his right eye. Ocular examination revealed best corrected visual acuity of 6/12 in right eye and 6/6 in left eye. Funduscopy revealed a neurosensory retinal detachment overlying the right fovea, with retinal pigment epithelial changes. Fundus fluorescein angiography (FFA) confirmed the diagnosis of CSR. He was taking steroids for his nasal problem. Advised him to stop the steroids and put the patient on NSAIDS. He recovered well. Then again after six months he came back with decreased vision in right eye to 6/60. Anterior segment was normal fundus revealed neurosensory detachment overlying the right fovea, diagnosis of CSR

was confirmed. This time 0.05ml of IVA(avastin) was given and he responded well. On further follow up his visual acuity recovered to 6/9. After one year he came back with complaints of decreased vision and some floaters coming in front of eye, visual acuity was counting finger. Fundus examination revealed a massive macular sub retinal haemorrhage in the right eye. FFA shows extensive masking (fig. 1). OCT also shows detachment of neurosensory retina with underlying blood (fig.2). Physical examination and investigations revealed no evidence of underlying systemic disease. Full blood count and coagulation screen were normal. We kept the patient for observation for at least 1 month but haemorrhage didn't resolved so he underwent 23G PPV. To our surprise very next day pt developed endophthalmitis, intravitreal vancomycin with ceftazidime and dexamethasone given endophthalmitis didn't resolved, planned for vitrectomy with silicon oil insertion with intravitreal vanco with ceftazidime. During vitrectomy there was touch to the posterior capsule of lens which leads to development of cataract for which patient underwent phaco with IOL implantation in sulcus and silicon oil removal. After 6 weeks patient recovered 6/12 vision and it remained stable till date.



**Fig. 1: Fundus examination revealed a massive macular sub retinal haemorrhage in the right eye. FFA shows extensive masking.**



**Fig. 2: OCT also shows detachment of neurosensory retina with underlying blood.**

## Discussion

Massive sub retinal macular haemorrhage can occur secondary to a number of causes such as choroidal neovascularisation (CNV), retinal artery macro aneurysm, idiopathic polypoidal choroidal vasculopathy, blood dyscrasia, or trauma. Histopathological analysis of patients with age related CNV, complicated by massive sub retinal haemorrhage may be associated with rupture of a large choroidal blood vessel.<sup>1</sup>

CNV is known to occur infrequently in patients with CSR treated with laser photocoagulation.<sup>2</sup> In only two previous cases have CNV developed spontaneously in patients with CSR.<sup>3</sup> Massive sub retinal haemorrhage, however, was not the feature in these two reported cases.

The pathogenesis of CSR has been disputed. Recent studies with ICG suggest focal choroidal hyper permeability as the possible initial event, leading to the formation of serous retinal pigment epithelial detachment. Excessive fluid accumulation then leads to pressure on the retinal pigment epithelium, resulting in either mechanical disruption or retinal pigment epithelial decompensation.<sup>4</sup> The chronic secondary retinal pigment epithelial changes, if extensive, could predispose to the development of CNV. In our patient, the sudden onset of haemorrhage in right eyes may in part be explained by the presence of disorganised and dysfunctional choroidal blood vessels. The latter leads to an initial increase in choroidal hyper permeability (hence the CSR) and later, the tendency to rupture suddenly resulting in massive haemorrhage (as illustrated by our case).

## Conclusion

Still it's a diagnostic dilemma what was the cause for developing subretinal bleed after CSR, may be there was polyps which we missed as ICG was not done.

## Acknowledgements

None

## Funding

None

## Competing Interests

None

## Reference

1. El Baba F, Jarrett WH, Harbin TS, et al. Massive hemorrhage complicating age-related macular degeneration: clinic pathologic correlation and role of anticoagulants. *Ophthalmology* 1986;93:1581–1592.
2. Schatz H, Yanuzzi L, Gitter KA. Sub retinal neovascularisation following argon laser photocoagulation treatment for central serous chorioretinopathy: complication or misdiagnosis? *Trans Am Acad Ophthalmology Otolaryngology* 1977;83:893–906.
3. Gromolin J. Choroidal neovascularisation and central serous retinopathy. *Can J Ophthalmol* 1989;24:20–23.
4. Guyer DR, Yannuzzi LA, Slakter JS, et al. Digital indocyanine green video angiography of central serous chorioretinopathy. *Arch Ophthalmol* 1994;112:1057–1062.