



A Rare Case Report of *Corynebacterium minutissimum* Causing Bacteremia In An Immunocompetent Patient

Sunita Gupta^{1*}, Vibha Bhargava¹, Rohit Jain¹, Prateek Goyal² and GN Gupta¹

¹Department of Pathology and Blood Transfusion, Santokba Durlabhji Memorial Hospital & Medical Research Institute, Jaipur, India

²Department of Orthopedics, Santokba Durlabhji Memorial Hospital & Medical Research Institute, Jaipur, India

ABSTRACT

Non-diphtherial *Corynebacteria* (NDC), which are also referred to as Diphtheroids are a widely diverse collection of bacteria. *Corynebacterium* species are normal flora of skin and mucous membrane. Up to now, the pathogenic potential of coryneform bacteria has been underestimated. In recent years, Coryneforms have emerged as important opportunistic pathogens in immunocompromised patients. Majority of the *Corynebacterium minutissimum* isolates are from erythrasma. Since its discovery in 1961 *Corynebacterium minutissimum* is rarely implicated in bacteremia. Though routinely considered as contaminants there are reports which establish NDM as a pathogen so it should not be discarded as contaminants in general. Hereby we report a case of bacteremia due to *Corynebacterium minutissimum* due to polytrauma by road accident.

Keywords: Non-diphtherial *Corynebacteria*, *Corynebacterium Minutissimum*, Blood Culture, Bacteremia

Introduction

Non diphtherial *Corynebacterium* species largely remains a neglected group with the traditional consideration of these organisms as contaminants.^[1] It is a gram-positive, non-spore forming, aerobic or facultatively anaerobic bacillus.^[2] They are found as colonizers of the skin and other tissues and in the environment.^[3] Although frequently considered as contaminants, these organisms have been associated with invasive disease, particularly in immunocompromised patients.^[1] The importance of these isolates in clinical settings is still undetermined, as evidenced by the lack of comprehensive data with a large number of isolates.

Although some cases of *C. minutissimum* infection have been reported, it has rarely been a causative agent of invasive extracutaneous infection.^[3] Reports on this group of organisms from India are sparse, except for a few case report concerning a particular species.^[1]

Case Report

We report a case of a young patient with *Corynebacterium minutissimum* bacteremia after polytrauma. Our patient was a 23 years old male who had a history of polytrauma due to road traffic accident one and a half months back. The Patient was brought to our hospital after first aid was given in a government hospital where fractured bones were splinted, catheter and central lines inserted. Patient had multiple bone fractures, Degloving injury and open wound over lumbosacral area with visible bony surface. Nailing was done in our hospital and slab was applied. Debridement and muscle repair was done over exposed

bone at the lumbosacral area. Split skin graft [SSG] was also done and patient was discharged.

Post discharge the patient complained of intermittent and high grade fever and was readmitted. On readmission CRP was 6.8 mg/dL. Hemoglobin was 10.6 gm/dL, Total Leucocyte Count was 7800/mm³, Neutrophils were 83.9%, and platelet 201×10³ /microlitre

Blood culture samples were sent from both hands which turned out to be positive within 48 hours. The specimen was cultured on 5% sheep blood agar plates at 35°C overnight. The growth on Sheep blood agar were smooth, moist grayish white, non hemolytic colonies. [Figure 1] There was no growth on Mac conkey agar. Gram stain done on colonies obtained from Blood agar showed Gram positive bacilli. [Figure 2] The bacteria were non-spore-forming, nonmotile and catalase-positive diphtheroid. Since similar type of colonies were seen on both hands blood culture samples and considering polytrauma history of the patient, It was considered pathogenic and Identification was confirmed using the Vitek 2 C System Anaerobic ANC card (BioMérieux, Durham, NC, USA) which confirmed it as *C. minutissimum*. Sensitivity was done by Disc diffusion method and it was found to be sensitive to Linezolid, Vancomycin, Teicoplanin, Tigecycline, Imipenam and resistant to Erythromycin, Clindamycin, Penicillin, Cephalosporin, Quinolones.

To reconfirm repeat blood culture samples were sent from both hands which also yielded the same bacteria viz *Corynebacterium minutissimum* with same sensitivity

pattern. Patient was initially on Meropenam and Clindamycin at time of admission. Antibiotics were changed to Tigecycline and Vancomycin after blood culture reports. Patient was also diagnosed with Acute Respiratory distress Syndrome and Infective endocarditis due to which the patient was intubated and mechanically ventilated. Colistin and Imipenam were also added.

Serum electrolytes, Urea and Creatinine were normal. Routine urine showed 8-10RBC /hpf and 10-15 WBCs /hpf

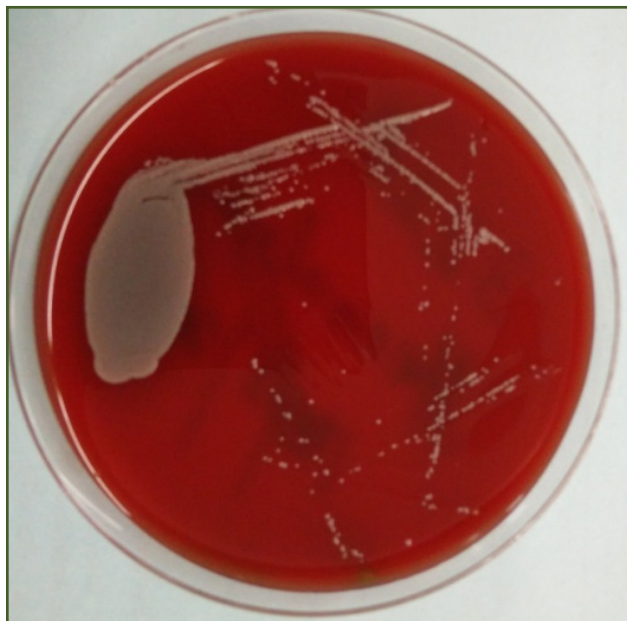

Fig. 1: The growth on Sheep blood agar were smooth, moist grayish white, non hemolytic colonies.

Discussion

Corynebacterium species have long been classified as skin contaminants, or “colonizers.” Not surprisingly, Clinicians often disregard blood cultures that yield these organisms². It is clearly stated that the recognition of infections caused by coryneform bacteria is highly dependent on the laboratory personnel’s ability to identify these species.^[4]

Due to the fact that almost all of them form part of a commensal flora at one or the other site in the body, absolute judgment is needed to find out its clinical significance^[1] Isolation from normally sterile sites of human body and repeated isolation of these bacteria from various clinical samples confirm their role in infection.^[6] The increasing size of the immunocompromised population and the more common use of intravascular access devices have likely contributed to this phenomenon.^[2]

In our case severe skin damage from trauma might have allowed *C. minutissimum* to cross what would normally

and Granular cast while urine culture was sterile. Another blood culture was sent after 5 days of starting of antibiotics which turned out to be negative.

Patient was afebrile after 10 days of starting antibiotics. As a result the central line was removed and the patient was put off the Ventilator. Patient again developed fever after 2-3 days. Blood cultures were sterile at that time. Patient was referred to AIIMS where valve replacement was done and the patient is healthy now.

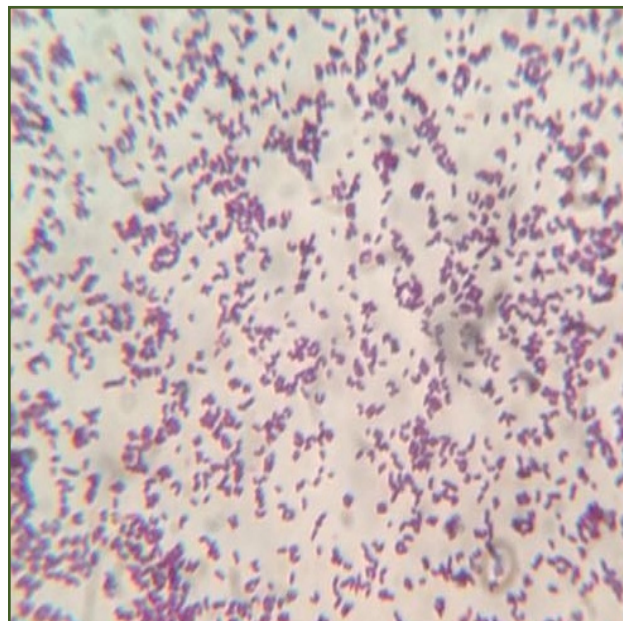


Fig. 2: Gram stain done on colonies obtained from Blood agar showed Gram positive bacilli

be an intact epithelial barrier. Isolate identified in our case was sensitive to vancomycin, linezolid, tigecycline, teicoplanin which correlates to various studies in which all the isolates were uniformly susceptible to vancomycin, linezolid, and tigecycline.^{[1], [5]}

Our isolate was resistant to Erythromycin, Clindamycin, Penicillin, Cephalosporin, Quinolones which correlates to studies where majority of the isolates were resistant to penicillin, beta lactam, erythromycin, clindamycin^{[1], [5]}

Due to lack of established CLSI guidelines for disc diffusion method for this group of organisms following approaches were adopted^[1]

- BSAC [British Society for antimicrobial guidelines] followed for Penicillin, Vancomycin, Ciprofloxacin
- For other antibiotics, the CLSI guidelines applicable for *Staphylococcus aureus* with *S. aureus* sp ATCC 25923 control strains were used.

Only few studies globally have characterized the human clinical isolates of NDC and their antimicrobial susceptibility patterns^[6]

Conclusion

It is now imperative that clinical microbiologists and clinicians understand the potential role of NDC in human infections and not consider all NDC as mere contaminants in laboratory

References

1. Reddy BS, Chaudhury A, Kalawat U, Jayaprada R, Reddy GSK, Ramana BV. Isolation, speciation, and antibiogram of clinically relevant non-diphtherial *Corynebacteria* (Diphtheroids). *Indian J Med Microbiol* 2012;30:52-7.
2. Granok A, Benjamin P, Garrett L. *Corynebacterium minutissimum* Bacteremia in an Immunocompetent Host with Cellulitis. *Clin infect dis* 2002;35:e40-2.
3. Shin JY, Lee WK, Seo YH, Park YS. Postoperative Abdominal Infection Caused by *Corynebacterium minutissimum*. *Infect Chemother* 2014;46:261-3.
4. Funke G, Graevenitz AV, Clarridge III JE, Bernara KA. Clinical Microbiology of coryneform bacteria. *Clin Microbiol Rev* 1997;10:125-59.
5. Rit K, Chakravorty B, Pal N, Saha R. Non diphtherial *corynebacterium* species isolation and their susceptibility profile from various clinical samples in a tertiary care hospital of eastern India. *J Sci* 2015;5:699-703.
6. Ramana K V, Vikram G, PadmaWali P, Anand K, Rao M, Rao S D, et al. Non Diphtheritic *Corynebacteria* (NDC) and Their Clinical Significance: Clinical Microbiologist's Perspective. *Am J Epidemiol and Infect Dis* 2014;2:83-7.

***Corresponding author:**

Dr Sunita Gupta, 12 Hathroi market, Above corporation bank ATM, Ajmer road, Jaipur, 302001, India

Phone: +91 9413342882

Email: drsunita_gupta@hotmail.com

Financial or other Competing Interests: None.

Date of Submission : 06.02.2017

Date of Acceptance : 12.04.2017

Date of Publication : 21.04.2017