



Angiomatoid Fibrous Histiocytoma: Can it be diagnosed in uncommon locations on morphological features?

Neeraj Dhameja¹, A Kunwar², Vikash^{*1}, S C Goel²

Department of Pathology, Institute of Medical Sciences, BHU, Varanasi, India

Department of Orthopaedics, Institute of Medical Sciences, BHU, Varanasi, India

Keywords: *Angiomatoid Fibrous Histiocytoma, Pseudoangiomatoid Spaces, Immunohistochemistry.*

Abstract

Angiomatoid Fibrous Histiocytoma is an uncommon soft tissue tumor of uncertain histogenesis with peak incidence in younger age group. The extremities are the commonest site though rarely it has been described in various other locations including bone. It shows certain unique histopathological and molecular features and has an indolent behaviour with recurrence in some cases and very rarely metastasis.

***Corresponding author:**

Dr Vikash, Department of Pathology, Institute of Medical Sciences, BHU, Varanasi-221005. INDIA
Mobile: +91-7704094687 Email: vikas25187@gmail.com

Introduction

Angiomatoid Fibrous Histiocytoma (AFH) is a rare soft tissue neoplasm of uncertain histogenesis commonly arising in children and young adults. It was first described by Enzinger^[1] in 1979 in soft tissues. It shows certain characteristic histopathological and molecular features with variable immunohistochemical positivity for different markers and has an indolent behaviour. Rarely it has been described in uncommon locations and bone is one such rare site with very few cases described so far.

Case Report

A 15 year child presented with pain right lower limb for 10 months and difficulty in walking for 6 months. . A plain X-ray was done which showed lytic lesion in the right proximal tibia. The cortical margin was regular and no cortical destruction was seen. Aneurysmal bone cyst was suspected on radiological findings and curettage was done (Fig.1).

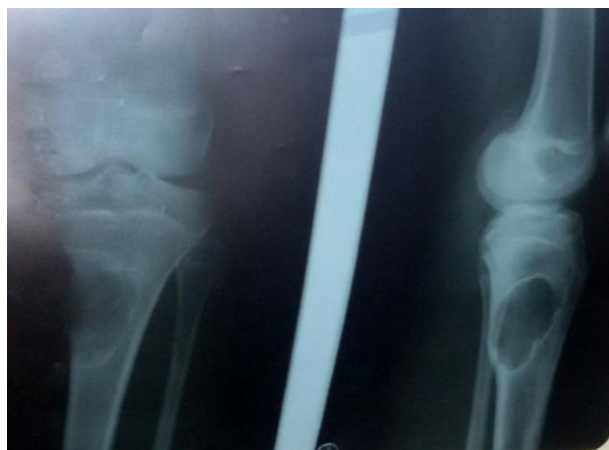

Fig.1: X-ray showing lytic lesion in proximal tibia

Histopathological examination showed a tumor with spindled and epithelioid cells having oval to elongated nuclei, fine chromatin and indistinct cytoplasmic boundaries in a fibrous background. No nuclear atypia, mitosis or necrosis was seen. Many dilated spaces without endothelial lining and filled with blood were present within the tumor cells. Dense lymphoid aggregates were also seen (Figs.2,3 and 4). No well defined fibrous capsule could be identified since it was curettage specimen. Based on these findings, a diagnosis of benign fibrous tumor was suspected and immunohistochemistry was done for desmin, epithelial membrane antigen (EMA), vimentin, CD68 and CD99. The tumor cells showed strong and diffuse positivity for vimentin, EMA and focal and weak positivity for desmin. CD68 and CD99 were focally positive (Figs.5,6 and 7). Molecular studies could not be done because of nonavailability. Based on the histopathological and

immunohistochemical findings, a diagnosis of angiomatoid fibrous histiocytoma was suggested. No further therapy was given. Presently the patient is on follow up and symptom free.

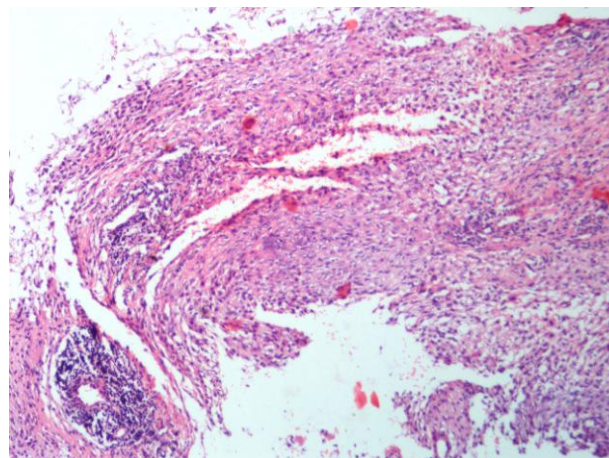


Fig. 2: Section showing spindle cells, pseudoangiomatoid spaces and lymphoid aggregates (H&E, 4x)

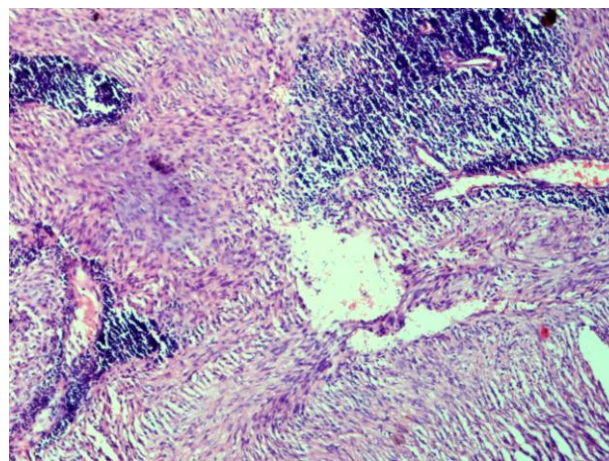


Fig. 3: Section showing spindle cells, pseudoangiomatoid spaces and lymphoid aggregates (H&E, 10x).

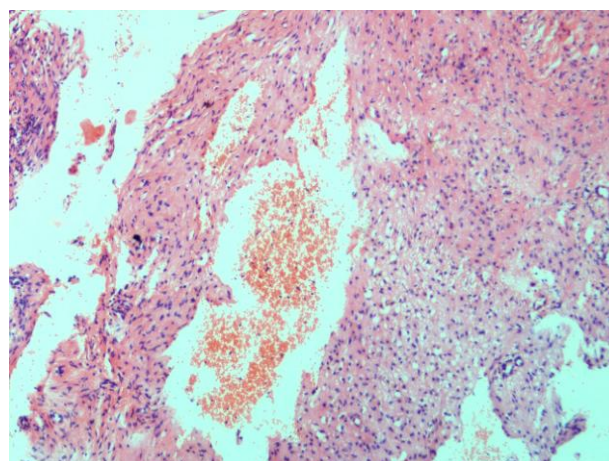


Fig.4. Pseudoangiomatoid spaces (10x10)

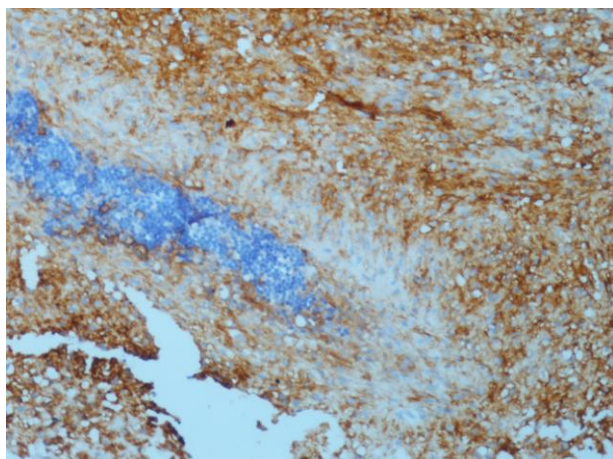


Fig.5. Tumor cells showing EMA positivity (EMA, 20x)

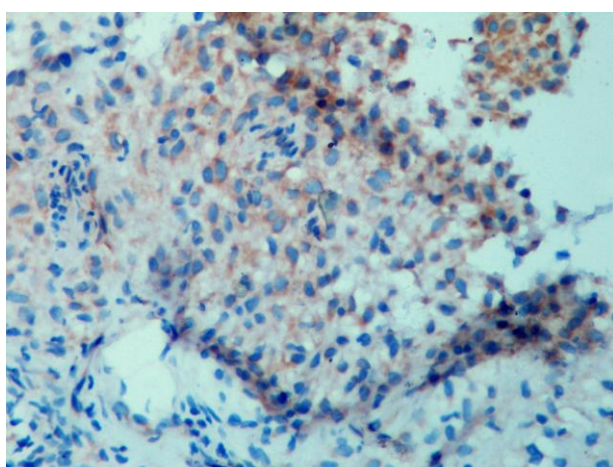


Fig.6. Tumor cells showing focal and weak desmin positivity (40x)

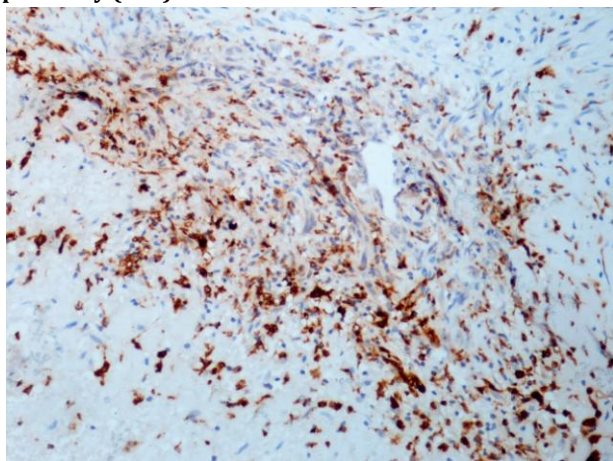


Fig.7. Tumor cells showing focal CD68 positivity (20x)

Discussion

Angiomatoid fibrous histiocytoma (AFH) is a rare soft tissue neoplasm arising in children and young adults. Enzinger^[1] in 1979 in a series of 41 cases first described this tumor in young individuals presenting with nodular subcutaneous growth in the extremities. The age range was 5-25 years with a median of 13 years. In this paper, it was called as angiomatoid malignant fibrous histiocytoma because of variable clinical

behaviour, three patients died of disease and 21 were alive with history of recurrence in 11 patients, one with recurrence and metastasis and one with metastasis. Now in the new WHO classification of soft tissue tumors,^[2] the malignant term is dropped and it is simply called as Angiomatoid fibrous histiocytoma because of very low malignant potential. In a large follow up study of 108 cases of AFH by Costa et al^[3] only one patient died of the disease (1%), hence, these authors advocated that this tumor be classified as fibrohistiocytic tumor of intermediate malignancy. AFH has characteristic histopathological features and reveal spindled to epithelioid cells arranged in fascicles or whorls and pseudoangiomatoid spaces without endothelial lining.^[2] Fibrous pseudocapsule and dense lymphoid aggregates with germinal centres are also seen. All these features (pseudoangiomatoid spaces, lymphoid aggregates and pseudocapsule) may be variably present and sometimes absent also, but spindled and epithelioid cells are always present.^[2] In the present case, since it was a curettage specimen, capsule could not be identified and lymphoid aggregates were intermixed with the spindled cells. AFH shows variable positivity for different markers. Desmin is positive in 50% of the cases and EMA is positive in around 40% of cases.^[2] CD68, CD99 are variably positive. In a study by Chen et al^[4] positivity for EMA, desmin, smooth muscle actin, CD68 and CD99 was found to be 100%, 63%, 43%, 100% and 100% respectively. Similarly, in a series of 13 cases of AFH by Kao et al^[5], EMA, Desmin and CD99 were positive in 56%, 78% and 100% of cases respectively. In the present case, EMA and vimentin were strongly and diffusely positive, desmin positivity was focal and weak and CD99 and CD68 were also focally positive. Cytogenetically it shows translocations involving different genes with EWSR1/CREB1 being the most common followed by EWSR1/ATF1 and FUS/ATF1. EWSR1, CREB1, ATF1 and FUS genes are located on chromosomes 22, 2, 12 and 16 respectively.^[4-6] AFH is primarily a soft tissue tumor, though occasionally it has been described in uncommon locations including bone.^[5] Only three primary bone AFH have been described so far.^[7] Imaging characteristics of AFH are described in one case report showing expansile lytic lesion in left ischium on plain Xray and multiple fluid levels with septations on MRI.^[8] A calcifying sclerosing variant of AFH in bone mimicking osteosarcoma histologically and radiologically but showing EWSR1-ATF1 translocation was described in one case report.^[9]

Prognostically, AFH has an indolent behaviour with 2-11% recurrences and less than 1% metastasis.^[2] Primary treatment is surgical excision.

Conclusion

In conclusion, we have described a rare case of Angiomatoid fibrous histiocyteoma in tibia in a child based on presence of spindled cells, cystic spaces and lymphoid aggregates with vimentin, EMA and weak desmin positivity, however, molecular studies should be done for characteristic translocation which we could not do because of nonavailability. AFH should be considered in differential diagnosis when above said morphological features are present in tumors of younger age group and appropriate immunohistochemical and molecular markers should be done if available because AFH is a tumor of intermediate biologic potential and patient needs follow-up.

Acknowledgements

Department of Pathology.

Funding

None.

Competing Interests

None declared.

References

1. Enzinger FM. Angiomatoid malignant fibrous histiocyteoma. A distinct fibrohistiocytic tumor of children and young adults simulating a vascular neoplasm. *Cancer* 1979;44:2147-57.
2. Smith JCF, Cin PD. Angiomatoid fibrous histiocyteoma. In: Fletcher CDM, Unni KK, Mertens F, editors. *Pathology and Genetics of Tumours of Soft Tissue and Bone*. Lyon:IARC Press;2002.p194-5..
3. Costa MJ, Weiss S. Angiomatoid Malignant Fibrous Histiocyteoma: A Follow-up Study of 108 Cases with Evaluation of Possible Histologic Predictors of Outcome. *Am J Surg Pathol* 1990;14:1126-32.
4. Chen G, Folpe AL, Colby TV, Sittampalam K, Patey M, Chen MG, et al. Angiomatoid fibrous histiocyteoma: unusual sites and unusual morphology. *Modern Pathology* 2011;24: 1560-70.
5. Kao Y-C, Lan J, Tai H-C, Li C-F, Liu K-W, Tsai J-W, et al. Angiomatoid fibrous histiocyteoma: clinicopathological and molecular characterisation with emphasis on variant histomorphology. *J Clin Pathol* 2014; 67:210-15.
6. Thway K. Angiomatoid Fibrous Histiocyteoma A Review With Recent Genetic Findings. *Arch Pathol Lab Med*.2008;132:273-77.
7. Inwards CY, Oliveira AM. Tumors of the osteoarticular system. In: Fletcher CDM, editor. *Diagnostic Histopathology of Tumors*. 4thed. Philadelphia: Elsevier-Saunders; 2013. 1871-1932.
8. Petrey WB, LeGallo RD, Fox MG, Gaskin CM. Imaging characteristics of angiomatoid fibrous histiocyteoma of bone. *Skeletal Radiol*. 2011;40:233-37.
9. Mangham DC, Williams A, Lalam RK, Brundler M-A, Leahy MG, Cool WP. Angiomatoid Fibrous Histiocyteoma of Bone: A Calcifying Sclerosing Variant Mimicking Osteosarcoma. *Am J Surg Pathol* 2010; 34:279-85.