



Primary Epithelioid Sarcoma of Forearm with Axillary Lymphnode Metastasis: A rare case report

Ankur Singh Kshatriya*, Nisha Gupta, Sameep Garg, Mitsu Vaishnav

Department of Pathology, Shri M.P. Shah Govt. Medical College, Jamnagar, Gujarat India

Keywords: *Epithelioid Sarcoma, Malignant Mesenchymal Tumour, Squamous Cell Carcinoma, FNAC.*

Abstract

Primary epithelioid sarcoma is a rare, slow growing malignant mesenchymal tumour, which may mimics a benign granulomatous lesion clinically and cytologically, leading to misdiagnosis. This is typically present as a subcutaneous or deep dermal mass in distal portions of the extremities with strong propensity for local recurrence and metastasis. Cytologically it is very challenging to diagnose epithelioid sarcoma as it may mimics synovial sarcoma, malignant melanoma, squamous cell carcinoma and epithelioid angiosarcoma. In this report we are describing the cytological features of epithelioid sarcoma with emphasizing on fine needle aspiration cytology as the first line of investigation.

***Corresponding author:**

Dr. Ankur Singh Kshatriya, A-141, Meera Park, Narayan Nagar, Khodiyar Nagar, Ahmedabad– 382350, Gujarat, India
Phone no. +91-9810087148; Email id- dr.ankursingh@gmail.com

Introduction

Primary epithelioid sarcoma is a rare, slow growing malignant mesenchymal tumour, which may mimics a benign granulomatous lesion clinically and cytologically, leading to misdiagnosis. This is first described by Enzinger in 1970.¹ Most frequent sites include fingers, hands, and forearms, and less commonly, lower leg, buttocks, and thighs. It is most prevalent in young adults, with a male predominance. This rare soft-tissue sarcoma typically present as a subcutaneous or deep dermal mass in distal portions of the extremities with strong propensity for local recurrence and metastasis.¹ it is typically present as a nodule or ulcer with a central area of necrosis resulting in a granuloma-like appearance, because of this it is easily be confused cytologically and histologically with a variety of benign and malignant lesions because of the general bland appearance of the cells, their epithelial differentiation, and the geographic necrosis. The differential diagnosis includes granulomatous processes, melanoma, squamous cell carcinoma, and adenocarcinomas. The fine-needle aspiration cytology (FNAC) of epithelioid sarcoma has not been extensively described.² but FNAC has played an increased role in the preoperative diagnosis of soft tissue tumors because of its high sensitivity and low cost.³ In this report we are describing the cytological features of epithelioid sarcoma with emphasizing on FNAC as the first line of investigation.

Case Report

A 29-years-old male patient was presented in the surgical outpatient department with complain of a rapidly growing painful mass on the right forearm. There was axillary lymphadenopathy in the same arm on physical examination. There was no other associated symptom. This patient was diagnosed and treated for the inflammatory condition but after one week swelling was not reduced. Other investigations like complete blood count and serum biochemistry were unremarkable, and culture for mycobacteria, fungi and bacteria were negative. X-ray of right forearm revealed a soft tissue shadow without bone involvement. The patient was referred for FNAC. On examination, A 5x4 cm sized swelling on the right forearm with normal overlying skin and firm in consistency at periphery with central soft consistency. FNAC was taken and hemorrhagic material obtained. Smears were prepared & fixed in methanol and stained with Hematoxylin and eosin stain (H&E) and Papanicolaou (PAP) stain.

Microscopic Examination: H&E and PAP stained smear of FNAC was highly cellular which showed clusters as well as dispersed round to polygonal cells with

interspersed spindle cells having which showed abundant eosinophilic cytoplasm and mild pleomorphism. Nuclei of the cells were large vesicular and eccentrically located giving the cells a plasmacytoid appearance with small but clearly visible nucleoli in necrotic background and occasionally multinucleated giant cells were also observed (fig.1&2). There was no phagocytic activity and other inflammatory cells. Similar cytological findings were also observed in axillary lymphnode FNAC. With all these features cytological diagnosis of malignant soft tissue tumour, epithelioid sarcoma with lymphnode metastasis was made.

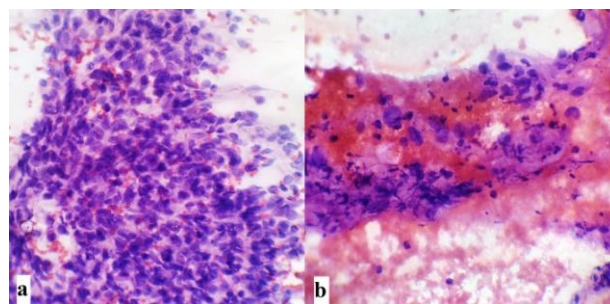


Figure 1 a) Clusters of round to polygonal cells with abundant eosinophilic cytoplasm and mild pleomorphism and large vesicular and eccentrically located nuclei with small but clearly visible nucleoli (H&E x400). b) Epithelioid cells of the cells in necrotic background (H&E x400)

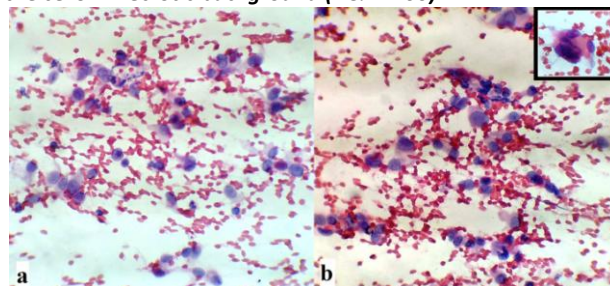


Figure 2 (a & b) Shows dispersed round to polygonal cells with abundant eosinophilic cytoplasm and large vesicular and eccentrically placed nuclei giving plasmacytoid appearance with clearly visible small nucleoli and occasionally multinucleated giant cells (Inset) (H&E x400).

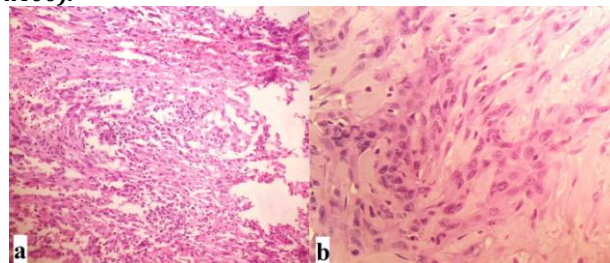


Figure 3 Oval to polygonal cells with moderate to abundant eosinophilic cytoplasm with vesicular nucleus, moderate atypia and small nucleolus with hyalinization. a) H&E x100 b) H&E x400

Subsequent incisional biopsy from the lesion was taken which showed mixed proliferation of oval to polygonal cells with moderate to abundant eosinophilic cytoplasm with vesicular nucleus, moderate atypia and small nuc-

leolus with hyalinisation (fig.3). Scattered rhabdoid like cells characterized by abundant glassy cytoplasm, eccentric nuclei and prominent nucleoli were also observed. There was mild mitotic activity also observed. Diagnosis of epithelioid sarcoma was made on histopathology.

Immunohistochemistry (IHC) showed positivity for cytokeratin, epithelial membrane antigen, vimentin and CD 34 while S-100 and CD31 were negative. The final diagnosis of epithelioid sarcoma was confirmed.

Discussion

Epithelioid sarcoma is a rare soft tissue sarcoma which was originally described by Laskowski as a sarcoma aponeuroticum in 1961. Later on in 1970 Enzinger gave the name epithelioid sarcoma.¹ It is rare soft tissue tumour accounts less than 1% of the all soft tissue neoplasms.⁴ it is mostly present in young adult age group with male predominance.^{4,5} Mostly seen on distal extremities⁴ but this tumor can also occur in the trunk or head and neck. It presents as a slowly growing painless or painful nodule with or without ulceration which is easily misdiagnosed as inflammatory process like indurated ulcer, infected wart, ulcerated squamous cell carcinoma or granulomatous process on FNAC.⁵ This is frequently metastasises through lymphatics and vascular channels and has shown a recurrence rate of up to 80% cases.⁶ It is quite difficult to diagnose epithelioid sarcoma on FNAC but role of FNAC in diagnosing this tumour is fairly documented as well as debated. FNAC may play an important role in detection of recurrence and metastasis.⁷

On cytological evaluation it shows clusters as well as dispersed oval to polygonal or epithelioid to spindled cells having mild to moderate pleomorphism⁸ with abundant eosinophilic cytoplasm and centre to eccentrically placed large round to oval nuclei giving plasmacytoid appearance to the cells with prominent nucleoli. Cytologically it is often misdiagnosed or confused with squamous cell carcinoma, malignant melanoma and benign epithelial neoplasm or a reactive histiocytic process.⁹ Unusual appearance of this sarcoma creates challenge for the cytopathologist because of the similar appearance of many nonneoplastic and neoplastic lesions.

FNAC can be used to diagnose the primary lesion as well as lymphnode metastasis. But the specific diagnosis of epithelioid sarcoma may be difficult in lymph node, because granulomatous lesions and metastatic carcinomas are more frequently seen in the lymph nodes.

In differential diagnosis on cytology, Squamous cell carcinoma shares many cytologic features with epithelioid sarcoma such as an epithelioid appearance, pres-

ence of spindle cells, tadpole cells, and inflammatory infiltrate.

The granulomatous appearance of classic epithelioid sarcoma can resemble a benign granulomatous lesion, especially in lymph node FNAC. However, the clinical presentation, the cellular atypia, presence of single cells with cytologic features of epithelioid sarcoma would be helpful in the differential diagnosis. On IHC, epithelioid sarcoma is immunoreactive for cytokeratin, whereas granulomatous lesions are not reactive.

Melanoma can be differentiated by the identification of melanin and the immunoreactivity for S-100, HMB-45, and A103.

Differentiation from synovial sarcoma can be difficult as this tumor also arises in the extremities and within the same age group. Cytologically, synovial sarcoma also shows the presence of epithelioid cells and spindle cells with immunoreactivity for cytokeratin and epithelial membrane antigen but this can be differentiated as aspirate of synovial sarcomas are usually more cellular and usually there is no inflammatory infiltrate in the background. Also, synovial sarcomas are not immunoreactive for CD34 as opposed to approximately 50% of epithelioid sarcomas, which are positive.¹⁰

Epithelioid angiosarcoma have haemorrhagic aspirates showing dispersed cells, cell groups and cell aggregates of pleomorphic cell population with predominant spindle cell and few epithelial-like cells arranged in acinar-like structures having variable nuclear atypia. On IHC they show positivity with CD 31, CD 34 and factor VIII.

Conclusion

Cytological diagnosis of epithelioid sarcoma is difficult and challenging but with good clinicopathological correlation, better knowledge and familiarity of cytomorphology of epithelioid sarcoma, pathologist can diagnose this lesion even on FNAC. The immunocytochemistry is also invariably useful.

Acknowledgements

We would like to thank Dr. Pravina M. Santwani, Professor & Head and technical staff of Department of Pathology, M.P. Shah Govt. Medical College, Jamnagar for their help and support in the study.

Funding

None.

Competing Interests

None declared.

References

1. Enzinger FM. Epithelioid sarcoma: a sarcoma simulating a granuloma or a carcinoma. *Cancer*. 1970;26:1029-41.
2. Barwad A, Dey P, Das A. Fine needle aspiration cytology of epithelioid sarcoma. *Diagn Cytopathol* 2011;39:517-20.
3. Willén H, Akerman M, Carlen B. Fine needle aspiration (FNA) in the diagnosis of soft tissue tumours; a review of 22 years experience. *Cytopathology* 1995;6(4):236–47.
4. Chase DR, Enzinger FM. Epithelioid sarcoma. Diagnosis, prognostic indicators, and treatment. *Am J Surg Pathol* 1985;9:241-63.
5. Prat J, Woodruff JM, Marcove RC. Epithelioid sarcoma: An analysis of 22 cases indicating the prognostic significance of vascular invasion and regional lymph node metastasis. *Cancer* 1978;41:1472-87.
6. Linscheid RL. Primary epithelioid sarcoma of the hand and forearm- a review of thirteen cases. *J Bone Joint Surg* 1974; 56:458-65.
7. Willén H, Akerman M, Carlén B. Fine needle aspiration (FNA) in the diagnosis of soft tissue tumours; a review of 22 years experience. *Cytopathology* 1995;6:236-47.
8. Lemos MM, Chaves P, Mendonça ME. Is pre-operative cytologic diagnosis of epithelioid sarcoma possible? *Diagn Cytopathol* 2008;36:780-6.
9. Cardillo M, Zakowski MF, Lin O. Fine-needle aspiration of epithelioid sarcoma: Cytology findings in nine cases. *Cancer* 2001;93:246-51.
10. Niemann TH, Bottles K. Cytologic diagnosis of metastatic epithelioid sarcoma. A cytologic mimic of squamous cell carcinoma. *Am J Clin Pathol* 1993;100(2):171–3.