



A Case Series of Retinochoroidal Toxoplasmosis from Western India: Guide to Salient Features, Diagnosis and Treatment

Deepen Sheth, Pandurang Kulkarni, Sundaram Natarajan

Department of Vitreoretinal & Uveitis Services, Aditya Jyot Eye Hospital Pvt. Ltd., Wadala, Mumbai, India.

Keywords: *Toxoplasmosis, Posterior Uveitis, Retinochoroiditis, Floaters*

ABSTRACT

Background: To study a series of cases of retinochoroidal toxoplasmosis with special mention of its clinical features, investigations & treatment. Although rare, it represents a significant number of all causes of posterior uveitis. Settings and Design: Retrospective Observational study.

Methods: 5 cases of primary and 2 cases of recurrence of acquired ocular toxoplasmosis in immunocompetent adults, from western India are included in these series. We study the clinical features & optical coherence tomography & fundus fluorescein angiography characteristics and the outcome with the quadruple drug therapy.

Results: In our study, we confirm that presence of specific symptoms and classical signs along with typical fundus fluorescein angiography (FFA) & optical coherence tomography (OCT) findings makes the diagnosis precise. A positive serology further aids in the diagnosis. Treatment with the quadruple regimen resulted in good visual prognosis in all but one case complicated with scarring at macula.

Conclusions: This study revives the diagnostic findings and helps as a guide to identify this potentially treatable cause of visual morbidity.

***Corresponding author:**

Dr Deepen Sheth; Aditya Jyot Eye Hospital Pvt. Ltd., Plot No. 153, Road No. 9, Major Parmeshwaran Road, Opp S.I.W.S. College Gate No. 3, Wadala, Mumbai 400 031. India.
Phone numbers : Tel : +91-22-2417 7600. Mobile : 09619850581. E-mail:deepensheth@gmail.com

INTRODUCTION

Toxoplasma gondii is an ubiquitous obligate intracellular protozoa, infecting up to one third of world's population.¹⁻³ Once infected, it remains chronically persistent throughout life. It has recently been concluded that eye is an important site for the acquired disease.⁴⁻⁷ Thus toxoplasmosis is an important cause of visual impairment, it being responsible for a third to a half of all posterior uveitis cases.⁷⁻¹³ Acquired infections in immunocompetent individuals are usually asymptomatic. Diagnosis of such cases helps us to administer a treatment regimen which has proven good results. We present this series in an attempt to provide a guide in managing these patients.

MATERIALS AND METHODS

A total of 7 eyes, of 7 patients who were diagnosed to have retinochoroidal toxoplasmosis, are included in this series. 5 of them were diagnosed as acquired primary disease and 2 had recurrent disease.

The patients underwent thorough ophthalmic evaluation including visual acuity, intraocular pressure, anterior segment examination at slit lamp and posterior segment examination with indirect ophthalmoscopy at all visits. After provisional clinical diagnosis, they underwent optical coherence tomography & fundus photography (including autofluorescence) on day 1 & on 6 weeks after completion of the treatment regimen. Fundus fluorescein angiography was performed before commencing the treatment. Serological tests for IgG & IgM were also conducted for all the patients.

Classic regimen include a combination of oral sulfadiazine + pyrimethamine (or sulfamethoxazole + trimethoprim) and prednisolone.^{14,15} Oral clindamycin is added as a part of the quadruple therapy.^{16,17} All our patients received a regimen as in the table. (Table 1)

Table 1. Quadruple treatment regimen.

Oral drug	Dosage	Remarks
Sulfamethoxazole - Trimethoprim (double strength)	800 mg – 160 mg BD x 6 weeks	Well tolerated.
Prednisolone	40/30/20/10/5 mg OD ½ hour after breakfast (8 am) x 3 days each	To be started 2 days after the antibiotics, tapered and stopped before them*.
Clindamycin	300 mg QID x 6 weeks	Side effect : Pseudomembranous colitis†.

*Avoided in Case 7 as the lesion was away from macula & optic disc and the patient was not keen for steroid intake.

†Clindamycin is added to the classic regimen for the quadruple therapy. 2 patients (Case 2 & Case 6) reported loose stools while on the therapy. The drug was discontinued in the first week for Case 2 due to intolerance.

CASES :

Case 1: A 52-year-female patient came to us with blurring of vision and floaters in the right eye (RE) since 5 days. Anterior chamber showed minimal inflammation with occasional cells. Posterior segment showed attached retina, retinochoroiditis lower nasal to disc with localised vitritis & adjoining vasculitis (Fig. 1a). FFA RE showed a hypofluorescent lesion with border becoming hyperfluorescent at late phase (Fig. 2). OCT RE showed hyperreflective lesion with localised vitritis (Fig. 3a). Patient's response to treatment was excellent, as is evident with resolution of vitritis and lesion (Fig. 1b & 1c).

Case 2: A 17-year-male presented with a 6 day history of left eye (LE) decreased vision and nasal field appearing hazy. Upon examination he was diagnosed as paramacular active toxoplasmosis temporal to fovea (Fig. 3a & 3b) and trace vitreous cells. OCT showed evidence of submacular fluid (Fig. 5b). FFA examination demonstrated the classical progression of hypofluorescence to hyperfluorescence in the periphery of the lesion. Patient was discontinued of clindamycin within a week, due to loose stools. Treatment with the triple therapy resulted in an inactive retinochoroidal scar (Fig. 3e & 3f).

Case 3: A 35-year-male presented with recent onset of blurring and floaters in LE since 15 days. He gave a history of ocular toxoplasmosis 5 years back. On examination he was found to have recurrence of retinochoroidal toxoplasmosis, localised vitritis with serous retinal detachment and pigmented scar upper temporal quadrant (UTQ) in LE. Upon treatment his lesion resolved with residual vitreous debris, an UCVA of 6/5 in LE and resolution of the subretinal fluid.

Case 4: A 32-year-female came to our hospital with redness and floaters in LE since 10 days. She was diagnosed with active retinochoroiditis with overlying localised vitritis and vasculitis in LE.

Case 5: The above patient presented at 6 years with a recurrence at the margin of a previous pigmented scar (Fig. 3c & 3g) with diminution of vision. BCVA increased from 6/60 to 6/12p in LE at 6 weeks following resolution of the lesion.

Case 6: A 57-year-male complained of central blurring in RE since few days. He was diagnosed as acute retinochoroiditis with a positive serology. At 5 weeks of the therapy, clindamycin was stopped as he reported with complaints of frequent loose stools. His vision gradually deteriorated as opposed to other cases reported in our series. At 6 weeks, examination showed an inactive scar with a speck of hemorrhage (Fig. 4b & 5a). Patient was not keen on angiography & was lost to follow up.

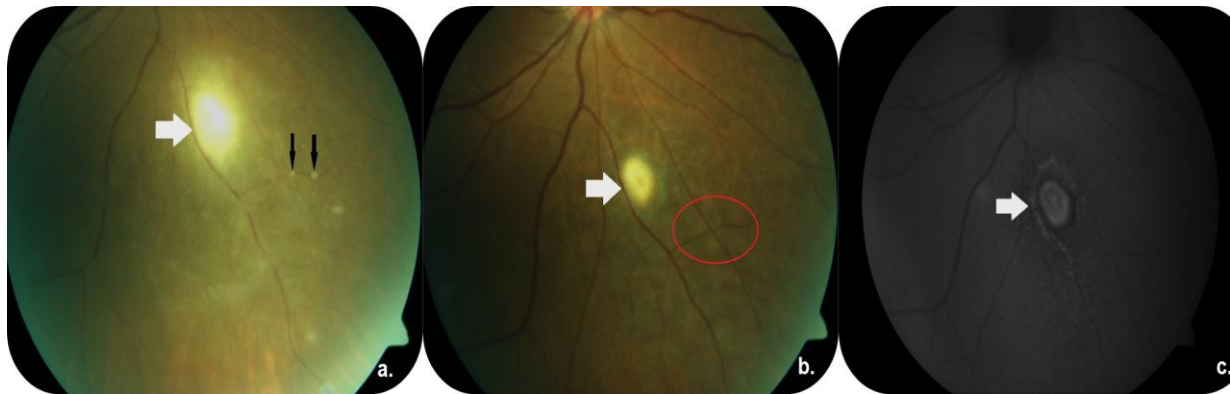


Figure 1 : Active whitish retinochoroiditis lesion (white arrowhead) with associated vasculitis (black arrows) {Figure 1a}. Colour fundus photo {Figure 1b} and autofluorescence photo {Figure 1c} showing resolved vitritis and healing lesion with hypofluorescent ring in the periphery (grey arrowhead). Vasculitis is also resolved (red oval).

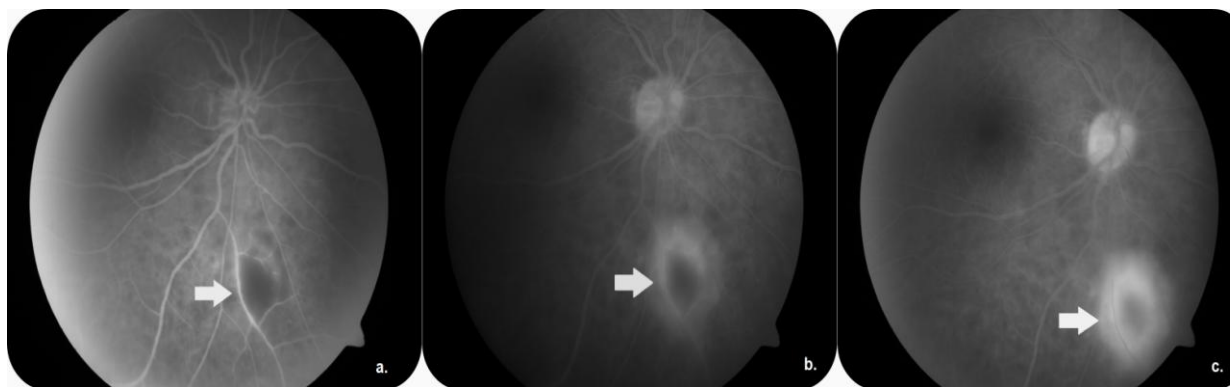


Figure 2 : Fundus Fluorescein Angiography showing the classical masking in the initial phase {Figure 2a} with late hyperfluorescence at the periphery {Figure 2b & 2c} (grey arrow).

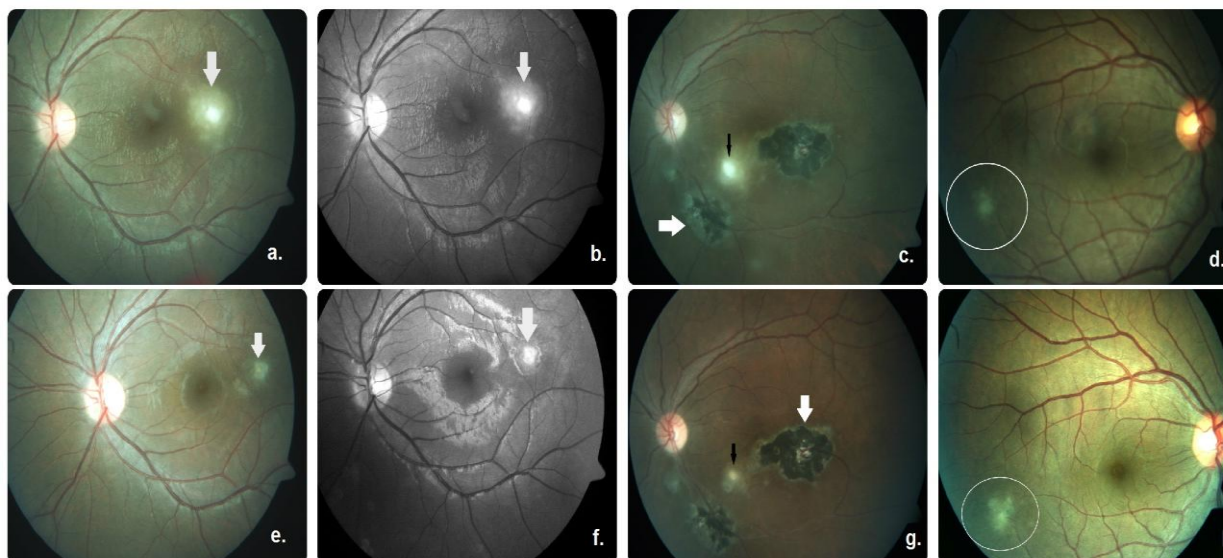


Figure 3 : Colour and red free photos showing active retinochoroiditis {Figure 3a, 3b, 3c, 3d} and inactive scar {Figure 3e, 3f, 3g, 3h}. ILM striae are evidently lost. Pigmented scars (white arrows) with recurrence & resolution (black arrows) seen near the margins.

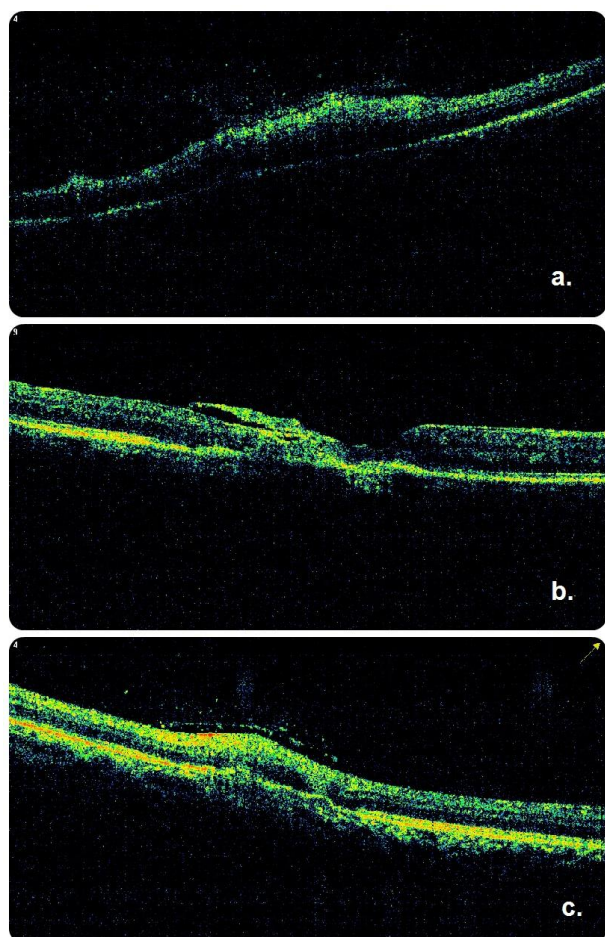


Figure 4 : Optical Coherence Tomography {Figure 4a & 4c} shows an elevated hyperreflective lesion with localised vitreitis and an epiretinal membrane. OCT of the right eye {Figure 4b} shows scar formation .

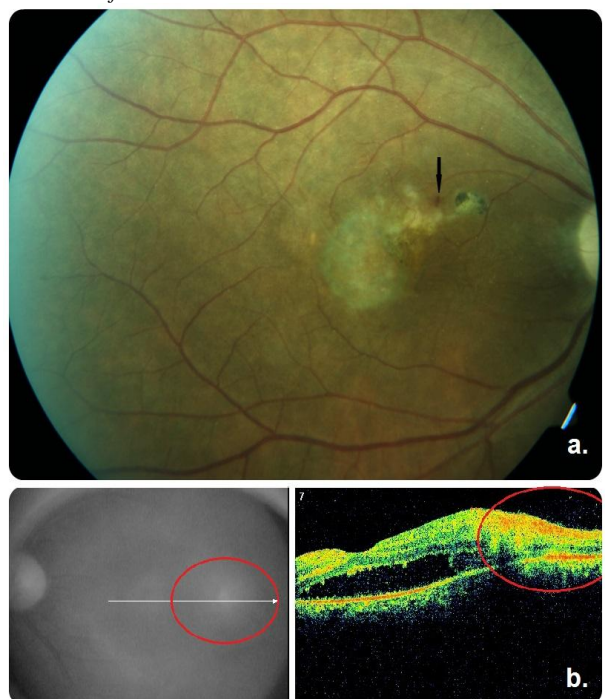


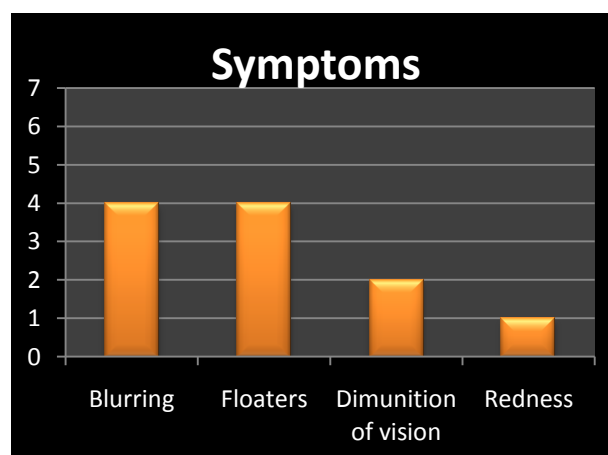
Figure 5 : Fundus photo {Figure 5a} showing evidence of a macular scar with a speck of hemorrhage (black arrow). OCT macula {Figure 5b} showing presence of subretinal fluid at the macula. Temporal to it is seen a hyperreflective lesion with localised vitreitis.

Case 7: A 29-years-male came for a check up for floaters in RE since 15 days. He was diagnosed with retino-choroiditis. FFA showed the classical hypo to hyperfluorescence of the lesion. Steroids were avoided as the patient was not keen & the lesion was away from the fovea and optic disc (Fig. 3d & 3h). OCT showed presence of localised vitreitis & epiretinal membrane (Fig. 4c).

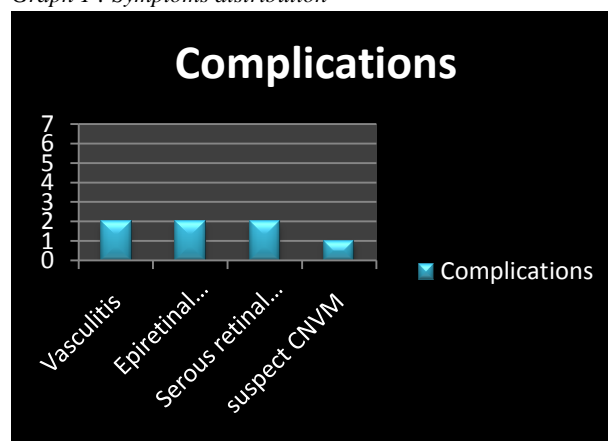
Institutional review board / Ethics Committee: This series was registered and approved by the institutional review board / ethics committees as it was a retrospective observational study.

RESULT

Symptoms : In our series, sudden onset of floaters and blurring of vision were reported as the most common presenting symptoms, while 2 patients presented with diminution of vision (Graph 1).



Graph 1 : Symptoms distribution



Graph 2 : Complications distribution.

Investigations : FFA & OCT provided sufficient confirmatory findings to diagnose the cases. IgG was positive in all the patients, while IgM was positive in Case 3.

Treatment : Most patients in the series received the complete course of the quadruple therapy. However, clindamycin was stopped in the first week for Case 2, due to complaints of severe loose stools. Case 6 also complained of loose stool, though he could tolerate the treatment and completed the course (Table 1).

Outcome : All patients showed visual improvement at the completion of therapy, except Case 6

(Table 2) which progressed to developing macular scar. Noted complications in our series include vasculitis, epiretinal membrane & serous retinal detachment (Table 2 & Graph 2).

Table 2. Patient data with complications & visual outcomes.

Cas e No.	Age/ Sex	Lateral- ity	Pre Rx	Post Rx	Complications
1.	52/F	RE	6/6	6/6	Vasculitis, Epiretinal membrane.
2.	17/M	LE	6/24	6/5	Serous retinal detachment
3.	35/M	LE	6/9	6/5	Serous retinal detachment
4.	32/F	LE	6/18	6/9	Vasculitis
5.	37/F	LE	6/60	6/18	-
6.	57/M	RE	6/6p	FC @ ½ m	CNVM sus- pect
7.	29/M	RE	6/6	6/5	Epiretinal membrane

DISCUSSION

Toxoplasma exists in three possible forms : 1. Oocysts (highly infective form) which results from the sexual cycle occurring in the intestinal epithelium of felines, 2. Tissue cysts (latent form in the chronic phase & contains bradyzoites), persisting in the skeletal muscles and brain, and, 3. Tachyzoites (actively replicating form), results in quick dissemination of the infection through the blood stream to various tissues, & in some reports, from brain to the eye via the optic nerve.¹

Humans acquire the infection either through the ingestion of poorly cooked meat containing tissue cysts, or ingestion of water or food contaminated with oocysts or through transplacental transmission of tachyzoites.¹

Acute retinochoroiditis results from active replication of tachyzoites in the tissue, predilection for retinal tissue is confirmed by its high affinity for retinal vascular endothelium.¹⁸ Active lesions upon resolution result in scar formation, which may harbour tissue cysts and result in a recurrence at a later date.

Symptoms : The common signs and symptoms of this cause of infectious uveitis are summarised below¹⁹ -

Anterior segment :

Granulomatous uveitis

Vitreitis :

Inflammation of the vitreous may be diffuse or more commonly localised (Fig. 4a & 4c) , resulting in blurring and/or floaters. Localised vitritis over the lesion may

lead to development of an epiretinal membrane (Fig. 4a & 4c) or vitreoretinal traction adjacent to the area of retinochoroiditis..

Retinochoroiditis :

- Primary: fluffy whitish lesion suggestive of focal retinal necrosis (Fig. 1a, 3a, 3b, 3c & 3d).
- Satellite lesion: active lesion at the edge of a well demarcated retinochoroidal pigmented scar (Fig. 3c & Fig. 3g).
- Headlight in fog (coined by Richard O Connor) : appearance of a white reflex in the presence of severe vitritis when a bright light is shown on the fundus (Fig. 1a).
- Vasculitis (Fig.1a) : vascular sheathing, exudation and arteriolar plaques (Kyrieleis' arteriolitis). Periphlebitis is noted more commonly than arteritis.
- Resolution of the active lesion results in atrophic retinochoroidal scar which heals from the periphery to the centre resulting in pigmentation (Fig. 3e, 3f, 3g & 3h).¹⁹

In our study, most patients presented with classical signs and symptoms suggestive of the condition, which was confirmed on investigations and treatment response.

Investigations :

Serology: A battery of serology tests include detection of anti-Toxoplasma antibody IgG, IgM, IgA & IgE. IgM antibodies appear in the first week of infection and generally decline over a few months. IgG antibodies appear in the second week of infection, peak in 6 to 8 weeks, and remain detectable for life, hence is not diagnostic. IgA and IgE antibodies can be detected during the acute phase of the infection and may be used for the identification of recently acquired infections.^{20,21} However, as Toxoplasma infects a third of the world's population, serology faintly plays an active role in deciding upon treatment.^{22,23}

Detection of Tgondii. : PCR technique or isolation from body fluids including aqueous & vitreous increases sensitivity & specificity.²⁴ These are expensive and not easily accessible methods, but may be useful in visually threatening non classical suspicious lesions.

Fundus fluorescein angiography: Hypofluorescence (due to masking by the lesion) at the early phase of the angiography, is followed by hyperfluorescence progressing towards the center of the lesion (Fig. 2).

Optical coherence tomography: Demonstrates localised vitritis, epiretinal membrane, tractional vitreous attachment, retinal edema, serous retinal detachment (Fig. 5b) and neovascular membrane.

Treatment : The main goals of the treatment are to reduce the duration and severity of symptoms of acute intraocular inflammation, and the risk of permanent vis-

ual loss and the risk of recurrent episodes. Various treatment regimen including triple/quadruple drugs are being followed all over the globe. Classic regimen include a combination of oral sulfadiazine + pyrimethamine (or sulfamethoxazole + trimethoprim) and prednisolone. Oral clindamycin is added as a part of the quadruple therapy. Other drugs that have been used include spiramycin, minocycline, azithromycin, atovaquone, and clarithromycin. Among all these drugs, atovaquone is the only drug which is active against cystic forms as well. However it is shown to only prolong reactivation and not prevent recurrences.²⁵ Recent reports have suggested an alternate promising treatment option with multiple intravitreal clindamycin (1.5mg/1mg, weekly or biweekly) +/- dexamethasone.^{15,26,27} Recently acquired cases have shown a better response profile with classic v/s intravitreal therapy.²⁷

Complications : Although rare, these include vasculitis, vascular occlusions, neovascularisation, epiretinal membrane, serous retinal detachment, macular edema, optic disc involvement, etc...²⁸

ACKNOWLEDGEMENTS

None.

FUNDING

None.

COMPETING INTERESTS

None declared.

REFERENCES

1. Tenter AM, Heckeroth AR, Weiss LM. *Toxoplasma gondii*: from animals to humans. *Int J Parasitol* 2000;30:1217–58.
2. Holland GN. Ocular toxoplasmosis: a global reassessment. Part I: epidemiology and course of disease. *Am J Ophthalmol* 2003;136:973–88.
3. Jones J, Kruszon-Moran D, Wilson M, et al. *Toxoplasma gondii* infection in the United States. *Am J Epidemiol* 2001;154:357–65.
4. Bowie WR, King AS. Outbreak of toxoplasmosis associated with municipal drinking water. *Lancet* 1997;350:173–8.
5. Burnett AJ, Shortt SG, Isaac-Renton J, et al. Multiple cases of acquired toxoplasmosis retinitis presenting in an outbreak. *Ophthalmology* 1998;105:1032–7.
6. Holland GN, Muccioli C, Silveira C, et al. Intraocular inflammatory reactions without focal necrotizing retinochoroiditis in patients with acquired systemic toxoplasmosis. *Am J Ophthalmol* 1999;128:413–20.
7. Glasner PD, Silveira C, Kruszon-Moran D, et al. An unusually high prevalence of ocular toxoplasmosis in southern Brazil. *Am J Ophthalmol* 1992;114:136–44.
8. Silveira C, Belfort R Jr, Burnier M, et al. Acquired toxoplasmosis infection as the cause of toxoplasmic retinochoroiditis in families. *Am J Ophthalmol* 1988;106:362–4.
9. Matos K, Muccioli C, Belfort R Jr, et al. Correlation between clinical diagnosis and PCR analysis of serum, aqueous, and vitreous samples in patients with inflammatory eye disease. *Arq Bras Oftalmol* 2007;70:109–14.
10. Woods AC, Jacobs L, Wood RM. A study of the role of toxoplasmosis in adult chorioretinitis. *Am J Ophthalmol* 1954;37:163–77.
11. McCannel CA, Holland GN, Helm CJ, et al. Causes of uveitis in the general practice of ophthalmology. UCLA Community-Based Uveitis Study Group. *Am J Ophthalmol* 1996;121:35–46.
12. Arevalo JF, Belfort R, Muccioli C, et al. Ocular toxoplasmosis in the developing world. *Int Ophthalmol Clin* 2010;50(2):57–69.
13. de-la-Torre A, López-Castillo CA, Rueda JC, et al. Clinical patterns of uveitis in two ophthalmology centres in Bogota, Colombia. *Clin Exp Ophthalmol* 2009 Jul;37(5):458–66.
14. Acers TE. Toxoplasmic retinochoroiditis: a double-blind therapeutic study. *Arch Ophthalmol* 1964;71:58–62.
15. Soheilian M, Sadoughi MM, Ghajarnia M, et al. Prospective randomized trial of trimethoprim/sulfamethoxazole versus pyrimethamine and sulfadiazine in the treatment of ocular toxoplasmosis. *Ophthalmology* 2005;11:1876–82.
16. Holland G, Lewis K. An update on current practices in the management of ocular toxoplasmosis. *Am J Ophthalmol* 2002;134(6):102–14.
17. Stanford MR, Gilbert RE. Treating ocular toxoplasmosis: current evidence. *Mem Inst Oswaldo Cruz* 2009;104(2):312–15.
18. Smith JR, Franc DT, Carter NS, et al. Susceptibility of retinal vascular endothelium to infection with *Toxoplasma gondii* tachyzoites. *Invest Ophthalmol Vis Sci* 2004;45:1157–61.
19. Emmanuelle Delair, Paul Latkany, A. Gwendolyn Noble, et al. Clinical Manifestations of ocular toxoplasmosis. *Ocular Immunology & Inflammation* 2011;19(2):91–102.
20. Adan A, Giral J, Alvarez G, et al. Pars planavitreotomy for vitreoretinal complications of ocular toxoplasmosis. *Eur J Ophthalmol* 2009;19:1039–43.

21. Francis JM, Joynson DH. Duration of specific immunoglobulin A antibody following acute toxoplasmosis as determined by enzyme immunoassay and immunosorbent agglutination assay. *Eur J ClinMicrobiol Infect Dis* 1993;12:556–9.
22. Gaete MIL, Malaguenio E, Cordeiro F, et al. Relacao entre IgA excretoranalagrimal X IgA sericanatoxoplasmose ocular com lesaoativa. *Dissertacao de Mestrado defendida em junho de 2003*;2007:03-08.
23. Holliman RE, Stevens PJ, Duffy KT, Johnson JD. Serological investigation of ocular toxoplasmosis. *Br J Ophthalmol* 1991;75:353–5.
24. Chapman DJ, Ashburn D, Ogston SA, et al. The relationship between ocular toxoplasmosis and levels of specific toxoplasma antibodies. *Epidemiol Infect* 1999;122:299–303.
25. Bou G, Figueroa MS, Marti-Belda P, et al. Value of PCR for detection of *Toxoplasma gondii* in aqueous humor and blood samples from immunocompetent patients with ocular toxoplasmosis. *J ClinMicrobiol* 1999;37:3465–8.
26. Winterhalter S, Severing K, Stammen J, et al. Does atovaquone prolong the disease free interval of toxoplasmicretinochoroiditis? *Graefes Arch ClinExpOphthalmol* 2010;248:1187–92.
27. Soheilian M, Ramezani A, Azimzadeh A, et al. Randomized trial of intravitreal clindamycin and dexamethasone versus pyrimethamine, sulfadiazine, and prednisolone in treatment of ocular toxoplasmosis. *Ophthalmology* 2011;118(1):134-41.
28. Kishore K, Conway MD, Peyman GA. Intravitreal-clindamycin and dexamethasone for toxoplasmicretinochoroiditis. *Ophthalmic Surg Lasers* 2001;32(3):183–92.