



Uterine Arteriovenous Malformation Accidentally Detected: A Case Report

Shikha Joshi*, Dipti Agrawal, Sunita Fotedar

Dept. of Gynecology and Obstetrics, Swami Dayanand Hospital Dilshad Garden, Delhi, India

Keywords: Arteriovenous Malformation, Embolisation, Mri, Ultrasound, Uterine Artery

ABSTRACT

Uterine arteriovenous malformation (AVM) is a rare condition and is potentially life-threatening condition. Uterine arteriovenous malformations result from formation of multiple arteriovenous fistulous communications within the uterus without an intervening capillary network.

This case report describes a 30-year-old woman with previous LSCS presented in emergency with episode of heavy vaginal bleeding with hypovolemic shock. Two weeks earlier, she had taken MTP pills for missed abortion. Transabdominal ultrasound (US) of the pelvis showed increased vascularity with multidirectional flow of the uterus with retained products. Colour Doppler was done which shows mass of size 35 mm with multiple small anechoic spaces in the anterior wall of cervix at the level of previous LSCS scar with increased systolic and diastolic blood flow with colour aliasing. MRI findings of an AVM include a focal uterine mass that consists of a group of distinct, serpiginous flow voids on T2W imaging. Beta HCG was 30mIU/mL. Patient was referred to higher centre for embolization of AVM which was performed successfully.

***Corresponding author:**

Dr Shikha Joshi, 27/76 Gali No 8 Vishwas Nagar Shahdara Delhi 110032, India

Phone : +91 09582647083

E-mail: drshikhajoshi@gmail.com

Introduction

Uterine arteriovenous malformation (UAVM) is a life-threatening rare condition. Bleeding is the major presenting symptom which may be postpartum, postabortal, menstrual (1,2). A UAVM consists of a proliferation of vascular channels with fistula formation. The size of these vessels can vary considerably. They are classified as congenital or acquired.(2,3)

Acquired uterine AVMs are usually traumatic, resulting from prior dilation and curettage (D&C), therapeutic abortion, uterine surgery, or direct uterine trauma.(1,4,5). Traditionally, uterine AVMs have been treated by uterine artery ligation or hysterectomy. Transcatheter uterine artery embolization is an alternative conservative management in patients who wish to preserve their fertility or young women .(6,7)

Case Report

A 30-year-old woman with previous LSCS presented with episode of heavy vaginal bleeding with hypovolemic shock. Two weeks earlier, she had taken MTP pills for missed abortion.

This was her second pregnancy previously she had a caesarean section for fetal distress two years back. She was diagnosed as 7 weeks missed abortion for which she had taken medical treatment from a local practitioner

On examination, she was afebrile and hemodynamically low with hemoglobin (Hb) level of 4.7 g% . Vaginal examination showed minimal bleeding with closed os . Human chorionic gonadotropin (hCG) level was less than 30mIU/mL.TAS and TVS showed empty uterus with an endometrial thickness of 4.3mm. There was increased vascularity of the uterus with prominent vessel seen on the left lateral wall of the uterus, which likely originated from the left uterine artery . A diagnosis of an AVM was

considered and required confirmation. Color Doppler (figure1) shows mass of size 35 mm with multiple small anechoic spaces in the anterior wall of cervix at the level of previous LSCS scar with increased systolic and diastolic blood flow with color aliasing

MRI findings of an AVM includes a focal uterine mass that consists of a group of distinct, serpiginous flow voids on T2W imaging with an ill-defined border that and is associated with prominent vascularity

Patient was referred to higher centre for embolisation of the AVM.Pelvic angiogram (figure 2) shows bilaterally enlarged tortuous uterine arteries .Embolisation of both uterine arteries were performed with 300–500 μ m and 700–1000 μ m polyvinyl alcohol (PVA). The post-embolisation arteriogram showed complete embolisation of the AVM with slow flow of contrast in both uterine arteries No complications were encountered. The patient's vaginal bleeding decreased post-embolisation and she was eventually discharged.During the follow up two weeks later, no repeat bout of bleeding with stable vitals.She reports having a regular menstrual cycle and has remained asymptomatic. The patient has also indicated here desire to conceive again in the future.

Discussion

Uterine vascular abnormalities are rare entities in gynaecology. However, it is a potentially life-threatening disorder in which patients present with vaginal bleeding that may be profuse and cause hemodynamic instability.

To date, there are fewer than 100 cases reported in the literature (1,7,8). AVM consists of proliferation of arterial and venous channels with fistula formation and a mixture of capillary-like vessels. Uterine AVM may be congenital or acquired (2,3)Congenital AVM is believed to arise from arrested vascular embryologic development resulting in

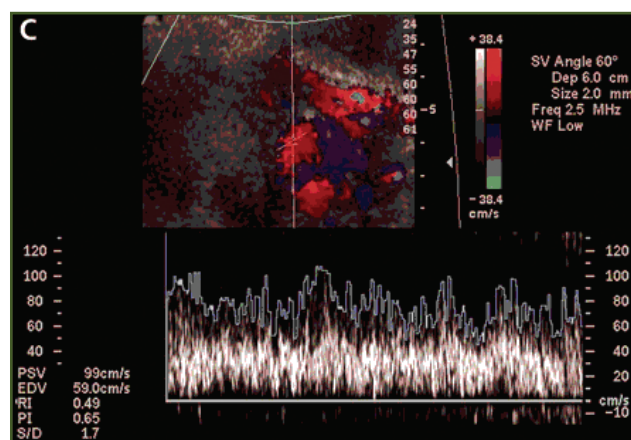


Fig. 1: Color Doppler Showing Increased Vascularity

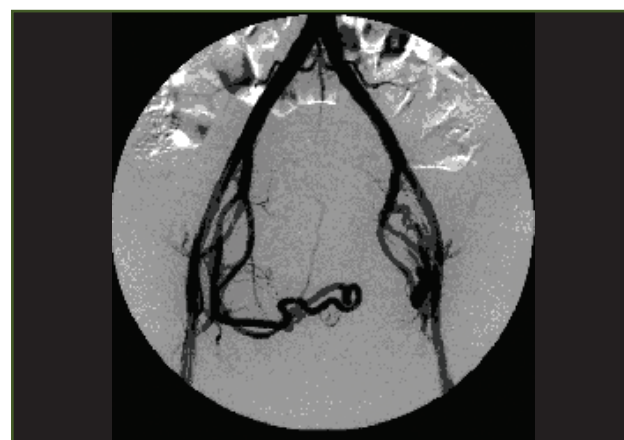

Fig. 2: Uterine Artery Angiogram

anomalous differentiation in the capillaries and abnormal communication, between arteries and veins. Acquired AVM are more common and usually follows a history of previous uterine trauma, such as curettage procedures, caesarean section, or pelvic surgery.

Doppler, MRI, angiogram are the gold standard in diagnosing AVM. Gray scale ultrasound (US) can detect the presence of multiple tubular or “spongy” anechoic or hypoechoic areas within the myometrium of a normal endometrium (2,4.) However, other conditions may present a similar appearance, such as retained products of conception, hemangioma, gestational trophoblastic disease. Thus, using colour and spectral Doppler US is important for obtaining more accurate information. In addition, uterine AVM will exhibit intensely vascular and multidirectional flow not considered in the differential diagnosis. Our patient had taken MTP pills for missed abortion, presented with heavy bleeding, low BP and anemia managed conservatively. Clinicians should raise high suspicion in their mind with such conditions where there is profuse bleeding with haemodynamically unstable. Curettage is non therapeutic and can often aggravate bleeding. Management of uterine AVM depends on the hemodynamic status, degree of bleeding, patient age, and desire for future fertility. Acute treatment involves stabilising the patient’s hemodynamic status, and stopping blood loss. Traditionally, a hysterectomy was the treatment of choice. However, the patient’s desire for future pregnancy is an important consideration, so UAE is treatment of choice.

Since the first description of a successful embolisation treatment for uterine AVM in 1986, it has been commonly used in the emergency setting as well as less urgent circumstances. Various embolic materials have been used, including polyvinyl alcohol, glue, detachable balloons, and haemostatic gelatine. Some cases may require repeat embolisation (4). In addition, because uterine AVM is commonly diagnosed in women of childbearing age, angiographic embolisation has made hysterectomy no longer necessary. However, hysterectomy remains the treatment of choice in post-menopausal patients or as an emergency treatment in life-threatening situations.

With conservative therapy several pregnancies after embolization have been reported with successful outcomes. Spontaneous resolution of uterine vascular malformations and subsequent pregnancy has also been reported in at least 5 cases. (8,9,10)

Conclusion

Uterine arteriovenous malformation (AVM) is a rare dangerous, life threatening yet treatable condition and if detected in time can avoid hysterectomy and save life.

Acknowledgements

None

Funding

None

Competing interests:

None declared

References

1. Fleming H, Ostor AG, Pickel H, Fortune DW. Arteriovenous malformations of the uterus. *Obstet Gynecol* 1989; 73:209–214
2. Polat Petal. Colour Doppler Ultrasound in the Evaluation of Uterine Vascular Abnormalities. *Radiographics*. 2002;22:47–53
3. Grivell R, Reid K, Mellor A. Uterine Arteriovenous Malformations: A review of the Current Literature. *Obstet Gynaecol Survey*. 2005;60(11):761–767.
4. Diwan RV, Brennan JN, Selim MA, et al. Sonographic diagnosis of arteriovenous malformation of the uterus and pelvis. *J Clin Ultrasound* 1983; 11:295–298.
5. Huang MW, Muradali D, Thurston WA, Burns PN, Wilson SR. Uterine arteriovenous malformations: gray scale and Doppler ultrasound features with MR imaging correlation. *Radiology* 1998; 206:115–123.
6. Garner EI, Meyerovitz M, Goldstein DP, Berkowitz RS. Successful term pregnancy after selective arterial embolization of symptomatic arteriovenous malformation in the setting of gestational trophoblastic tumor. *Gynecol Oncol* 2003; 88:69–72
7. Pope SL, Fleisher AC, Bream PR. Intramyometrial arteriovenous malformation. *J. Womens Imaging* 2003; 5:79–82.
8. Hoffman MK, Meilstrup JW, Shackelford P, Kaminski PF. Arteriovenous malformations of the uterus: an uncommon cause of vaginal bleeding. *Obstet Gynecol Surv* 1997; 52:736–740
9. Garner EI, Meyerovitz M, Goldstein DP, Berkowitz RS. Successful term pregnancy after selective arterial embolization of symptomatic arteriovenous malformation in the setting of gestational trophoblastic tumor. *Gynecol Oncol* 2003; 88:69–72
10. Y N Chia, C Yap, B S Tan. Pregnancy Following Embolisation of Uterine Arteriovenous Malformation – A Case Report. *Annals, Academy of Medicine, Singapore* 2003;32:658-60