

Non Syndromic Double Lip: A Rare Case Report

Manjima Sasidharan^{1*}, Viashali Kanhoba Keluskar² and Anjana Satish Bagewadi¹

¹Department of Oral medicine and Radiology, Educare Institute of Dental Sciences, Malappuram, Kerala, (India)

²Department of Oral medicine and Radiology, KLE VKIDS, Belgaum, Karnataka, (India)

ABSTRACT

Double lip is a rare oral congenital condition characterized by hypertrophic tissue on the inner aspect of the lip. Most of the cases are symptomatic except for the disfigurement of lips. Some cases are associated with Asher's syndrome. Dentist plays a key role in diagnosing the condition as it is limited to oral and perioral tissues. Here we report a case of nonsyndromic double in a young male patient.

Keywords: Double Lip, Upper Lip, Congenital, Syndrome

Introduction

Double lip is an uncommon developmental anomaly, affecting the lips in which a fold of excess or redundant labial tissue is apparent at rest or on smiling.[1] This is an oral developmental anomaly with a prevalence rate <1/10,00,000. A good number of cases are reported in the upper lip, though both upper and lower lips are occasionally involved. It has got no race or gender predilection however Palma and Taub, in a recent report in 2009, have suggested a male predilection of 7:1. [2] The deformity may be present at birth and become more prominent as the patient grows secondary to trauma. Also chronic lip sucking habit may give rise to double lip. Congenital variant may possibly occur in isolation or as a part of Ascher's syndrome. Double lip may present clinically as a single distinct entity or in conjugation with other manifestations like bifid uvula and cleft palate.[3, 4] We report a case of a non- syndromic congenital maxillary double lip in a 21 year old patient.

Case Report

A 21-year-old male patient reported to the Department of Oral and medicine and Radiology with the chief complaint of extra mass of tissues in the upper lip since birth. Unsightly appearance while smiling was the main concern of the patient. During examination, an extra fold of redundant tissue was present on the inner surface of the upper lip bilaterally. (Figure: 1) The extra fold of lip was more prominent on smiling and it was bilaterally asymmetrical. (Figure: 2) The overlying mucosal tissue appeared smooth with no surface changes. There was no pain and other associated symptoms. Blepharochalasis and thyroid enlargement was ruled out on further examination. Based on the history and clinical examination a provisional diagnosis of congenital bilateral upper double lip was

made. Patient was referred to Dept Oral surgery for surgical excision. Histopathologic report of the specimen showed normal labial mucosa with mucosal glands and capillaries. Patient was kept under follow up for 1 year and no recurrence was observed. (Figure: 3)

Discussion

The double lip may be present as a single entity or as a feature of syndrome. The exact cause is unknown but may be transmitted as an autosomal dominant disorder. The association of congenital double lip with other abnormalities as bifid uvula and cleft palate has been described.[5]

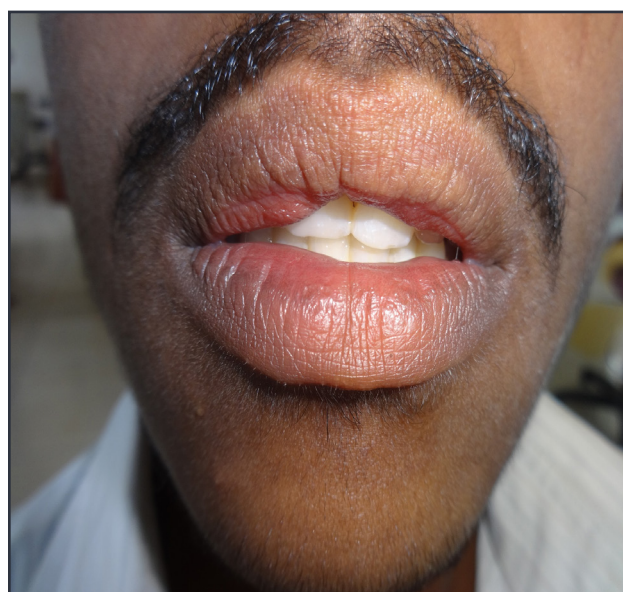

Fig. 1: Extra fold of redundant tissue seen on the inner surface of the upper lip bilaterally.

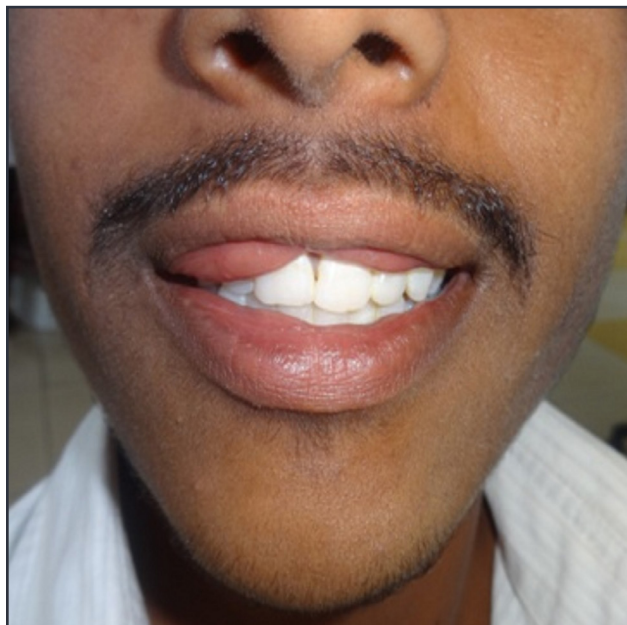

Fig. 2: Prominent extra fold of lip on smiling.

The congenital form of double lip is thought to arise during the second or third month of gestation from a persistence of the sulcus between the Pars Glabrosa and the Pars Villosa of the lip. During fetal development, the upper lip mucosa consists of two transverse zones, an outer zone, which is smooth and similar to skin, the Pars Glabrosa and the inner zone, which is villous and similar to the oral mucosa, the Pars Villosa.[6] Clinically on smiling, it gives the characteristic Cupid's bow appearance. Double lip can be distinguished from other lip swellings due to this particular "Cupid's bow" appearance or midline constriction due to upper labial frenum attachment.

Histopathological examination of the excised specimen from the lips shows hyperplastic mucous glands, loose areolar tissue, numerous blood-filled capillaries and perivascular infiltration with plasma cells and lymphocytes.⁷ The histopathology examination for the patient in this report showed normal labial mucosa with numerous hyperplastic mucous glands

The differential diagnosis of double lip should include other forms of chronic enlargement of the lip such as haemangioma, lymphangioma, angioedema, cheilitis glandularis, and glandular granulomatosis. These conditions, however, do not present with central constriction of the lip. [5]

The treatment of double lip is surgical. It is indicated for aesthetic reasons or if the excess tissue interfere s with

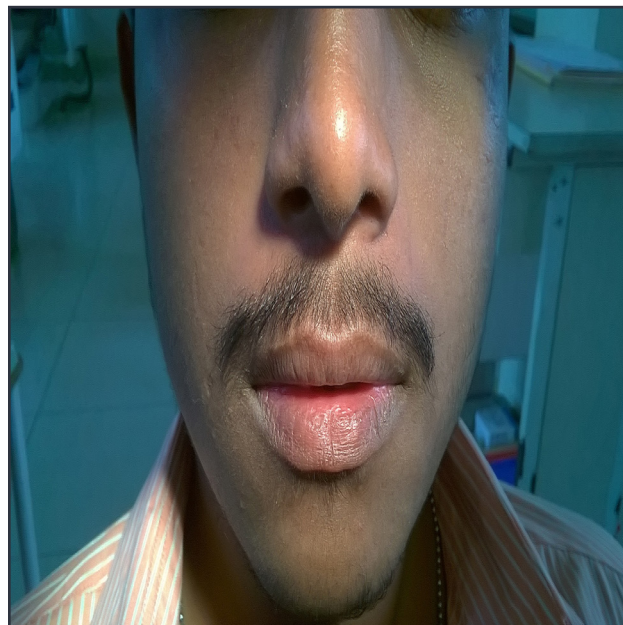


Fig. 3: Post-operative.

mastication and speech or leads to oral habits such as lip biting or sucking between teeth or maloccluding dentures. [7,8] Various surgical techniques to correct a double lip have been described, but simple excision through an elliptical incision is usually suggested. The patient in this report is kept under follow up since recurrence of the disease is rarely observed by some authors. [9]

Conclusion

In conclusion, this oral anomaly is of special interest for a reason that it is a very rare finding of head and neck region and first dentist is the person to diagnose the condition.

1. Desai VD, Das S. A rare case report: Non-syndromic double lip. *CHRISMED J Health Res* 2015; 2:150-2
2. John Spencer M. Daniels*Congenital double upper lip: A case report and review of the literature
3. Martins WD, Westphalen FH, Sandrin R, Campagnoli E. Congenital maxillary double lip: Review of the literature and report of a case. *J Can Dent Assoc* 2004; 70:466-8.
4. Suliman MT, Alhassan M. Double lip: Report of five cases and review of the literature. *Aesthet Surg J* 2007; 27:289-91.
5. Costa-Hanemann J.A., Tostes-Oliveira D. and Fernandez-Gomes M., James Da Silvados Anjos M., Sant'ana E. Congenital double lip associated to hemangiomas: report of a case. *Med. Oral*.2004; 9:155–158.)
6. Kara OC, Kara IG, Double Lip. *The Internet Journal of Otorhinolaryngology* 2000;1(1):Accessed30-1-2007.
7. Gorlin R.J., Pindborg J.J., Cohen M.M. 2nd ed. McGraw-Hill; New York: 1976. *Syndromes Of The Head And Neck*. pp. 253–255.)

8. Chidzonga MM, Mahomva L. Congenital double lower lip: report of a case. *Int J Paediatr Dent.* 2006;16:448–9.
9. Ali K. Ascher syndrome: a case report and review of the literature. *Oral Surg. Oral Med. Oral Pathol. Oral Radiol. Endod.* 2007; 103:e26–e28.

***Corresponding author:**

Dr. Manjima S, Senior Lecturer in Department of Oral medicine and Radiology, Educare Institute of Dental Sciences, Malappuram, Kerala, 676504 (India)

Email: drmanjimas@gmail.com

Financial or other Competing Interests: None.