

## Comparative Evaluation of Conventional Radiography and Color Doppler Ultrasound Imaging in Differentiating Periapical Lesions

Smitha J D\*, SrishaBasappa, Nishath Khanum, Santosh Kanwar, Archana Patil and Mahesh M S

Department of Oral Medicine and Radiology, Farooqia Dental College and Hospital Mysuru, Karnataka, India.

### ABSTRACT

**Background:** Pathological changes in body architecture and disease progression can be detected with radiographs. Accurate diagnosis of this pathological process is necessary for successful treatment and for predictable outcomes. One of the recent advances in achieving this is the advent of diagnostic ultrasonography in identification and differentiating the periapical lesions. Aim of the study is to assess and compare the diagnostic capability of conventional radiography and colour Doppler ultrasound imaging in the identification and differentiating the periapical lesions.

**Methods:** Twenty patients with periapical lesions of pulpal origin which were clinically diagnosed and indicated for extraction were selected for the study. Pre-operative periapical radiographs were obtained. Pre-operative ultrasound examination was performed and the images were assessed for the size, contents, vascular supply and to detect whether the lesion is a periapical abscess, periapical granuloma or periapical cyst. Extraction was performed including curettage of the periapical tissues to enable histopathological investigation, which provides the gold standard diagnosis. The results from the biopsies of the lesions were compared with radiological and ultrasound results and statistically analysed.

**Result:** Of the twenty cases studied, ultrasound could detect 4 periapical abscess, 9 periapical Granuloma and 7 periapical cysts. But histopathologically there were 4 periapical abscess, 7 periapical granulomas and 9 periapical cysts. Two of the periapical cysts were misdiagnosed as periapical Granuloma ultrasonographically. Correlation between ultrasonography and histopathology is 90 percent and between conventional radiography and ultrasonography is 90 percent. Sensitivity of this examination is 88.89 percent.

**Conclusion:** Ultrasound imaging has the potential to be used for the evaluation of periapical lesions of endodontic origin. However, further studies are required to establish a definite correlation.

**Keywords:** Colour Doppler, Conventional Radiography, Periapical Lesions, Ultrasound

### Introduction

Conventional radiographs play an important role in the detection, treatment, and follow-up of periapical lesions. However, routine radiographs cannot be relied upon due to the diffuse and infiltrative nature of the inflammatory process in bone, the inability of radiographic techniques to demonstrate non cortical radiolucencies.<sup>[1]</sup>

Digital radiography has been regarded as a viable alternative to film-based imaging. However, recent studies have demonstrated that digital radiography even when used with image processing and colour coding is no better than conventional radiography in the detection and measurement of periapical lesions.<sup>[2,3]</sup> Computed tomography (CT) has been used to make a differential diagnosis between periapical granulomas and periapical cysts and for the follow-up management of extensive periapical lesions. However, routine use of CT even with the aid of dose reduction methods is associated with high dosage of radiation.<sup>[4]</sup>

Magnetic resonance imaging (MRI) has been suggested as an alternative to X-ray based imaging modalities for

the visualization of periapical lesions. However, bone is better imaged by using conventional X-ray and CT than by using MRI. Also, MRI is claustrophobic, affects metallic implants, and expensive.<sup>[5]</sup> The use of ultrasound imaging with Colour Doppler for the diagnosis of periapical lesions of endodontic origin has been recently reported. Ultrasound examination is a non-invasive technique that offers advantages like ease of availability and portability, provision of real-time dynamic functional studies, speed of investigation, patient acceptability, cost-effectiveness, availability of images in digital form that are easy to read, store, and reproduce, and freedom from radiation hazards.<sup>[6]</sup> The purpose of this study was to assess and compare the diagnostic capability of conventional radiography and Colour Doppler ultrasound imaging in the identifying and differentiating the periapical lesions.

### Materials and Methods

Twenty patients with periapical lesions of pulpal origin which were clinically diagnosed and indicated for extraction were selected for the study. Pre-operative periapical radiographs were obtained using bisecting angle technique at 70 kVp, 8 mA, and Kodak E-speed film. The conventional

radiographs were processed. The radiographs were viewed and evaluated on a viewing box under normal operating illumination and detailed description of the periapical lesions was made. Based on clinical and radiological findings, the presence of a periapical lesion was confirmed. Pre-operative ultrasound examination was performed and the images were assessed for the size, contents, vascular supply and to detect whether the lesion is a periapical abscess, periapical granuloma or periapical cyst. Extraction was performed including curettage of the periapical tissues to enable histopathological investigation, which provides the gold standard diagnosis. The histopathology report was then compared with the description obtained from the ultrasound images. The study was conducted after obtaining approval from the Ethical Committee, Farooqia Dental College and Hospital, Mysore, Karnataka.

**Ultrasound Examination:** The equipment used in this study was an ultrasound machine Logic 500 MD MRS, Wipro-GE, Bangalore, India (USG with Doppler facility) with a high definition regular size linear array transducer probe having a frequency of 8-11 MHz. The patient was seated in the supine position and the operator seated in a rotating stool beside the bed of the patient. The area to be examined was covered with a layer of ultrasound transmission gel (Techno med). The ultrasonic probe was positioned extra orally corresponding to the apical area of the tooth against the skin at the corresponding external area. The position of the probe was changed slightly in order to obtain an adequate number of transverse and longitudinal scans. Colour Doppler was performed to assess blood flow. Information on the size of the lesion, its content and vascular supply was gained and recorded by means of ultrasound images. The sonographic images were analyzed and discussed with an expert sonologist. The reports were recorded and a tentative diagnosis between a periapical abscess, periapical granuloma and periapical cyst was made based on the principles of sonography. Periapical abscess: predominantly hypo echoic area with focal anechoic area, showing vascularity in some areas on colour Doppler examination [Figure 1].

Granuloma: a poorly defined hypo echoic area, showing rich vascular supply on Colour Doppler examination [Figure 2]. Cystic lesion: a hypo echoic well-contoured cavity surrounded by reinforced bone walls, filled with fluid and with no evidence of internal vascularization on Colour Doppler examination [Figure 3].

## Result

The patients experienced no discomfort during the sonographic examination. Sonographic images of the

periapical lesions were obtained in all the 20 cases. The data were tabulated. The results of ultrasound were correlated with radiographic and histological findings and were statistically analyzed. Four lesions showed both hypo echoic and anechoic regions, i.e., mixed echogenic patterns with numerous scattered internal echoes and varying density values within the lesion suggestive of periapical abscess. All the cases were confirmed as periapical abscess histopathologically. Correlation between ultrasonography and histopathology in cases of periapical abscess is 100%.

Nine lesions revealed hyper echoic or mixed content (showing both hyper echoic and hypo echoic areas) with poorly defined borders. The lesions showed evidence of internal vascularization on colour Doppler examination. All these cases were diagnosed as periapical granulomas. Histopathologically there were seven cases of granulomas. Correlation between ultrasonography and histopathology in cases of periapical granulomas is 77.7% (Graph 1, Graph 2). The sonographic examination revealed the presence of 7 lesions with well-defined contours and hypo echoic/ anechoic content. Acoustic enhancement was also seen. The lesions showed no evidence of internal vascularization with colour Doppler. These lesions were diagnosed as periapical cysts. Histopathology examination demonstrated the presence of 9 lesions diagnosed as periapical cysts. Correlation between ultrasonography and histopathology in cases of periapical cyst is 77.7% as shown in Table 1.

Two of the cysts were misdiagnosed as granulomas ultrasonographically. This may be due to presence of dense particles (cholesterol clefts in the infected cysts) or presence of keratin in odontogenic cysts. This is indicative of difference in the contents within the lesion which is reflective of disease process.

**Diagnostic Validity of Ultrasonography:** tp denotes true positive = 16 subjects, tn denotes true negative = 2 subject, fp refers to false positive = 2 subjects, fn is false negative = 0 subjects, and  $N$  is total number of patients = 20 subjects. Sensitivity is calculated to be 88.89%. Total efficacy of this examination is 90% (Graph 3)

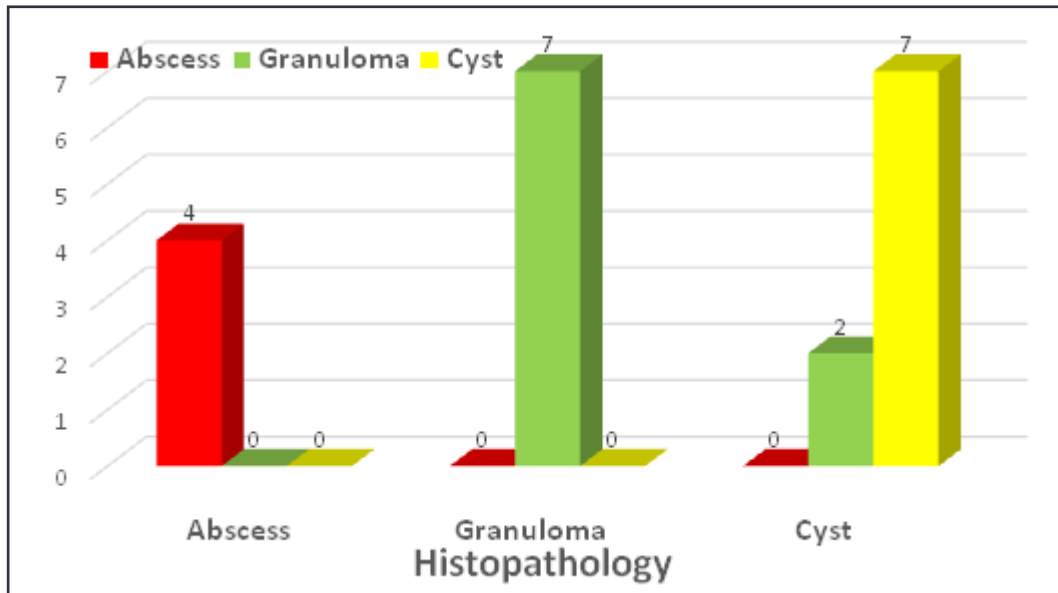
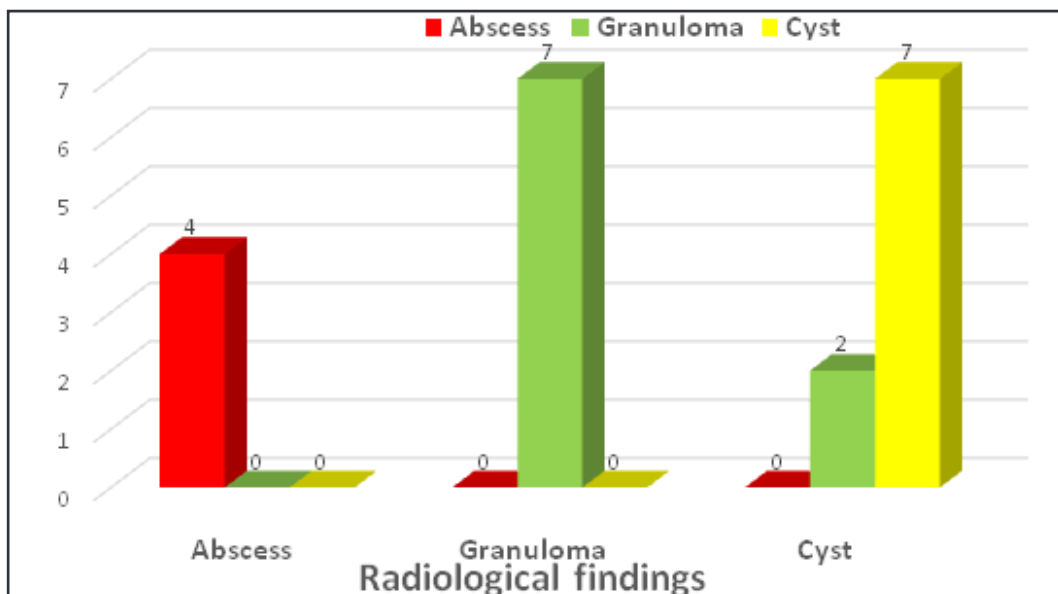
## Discussion

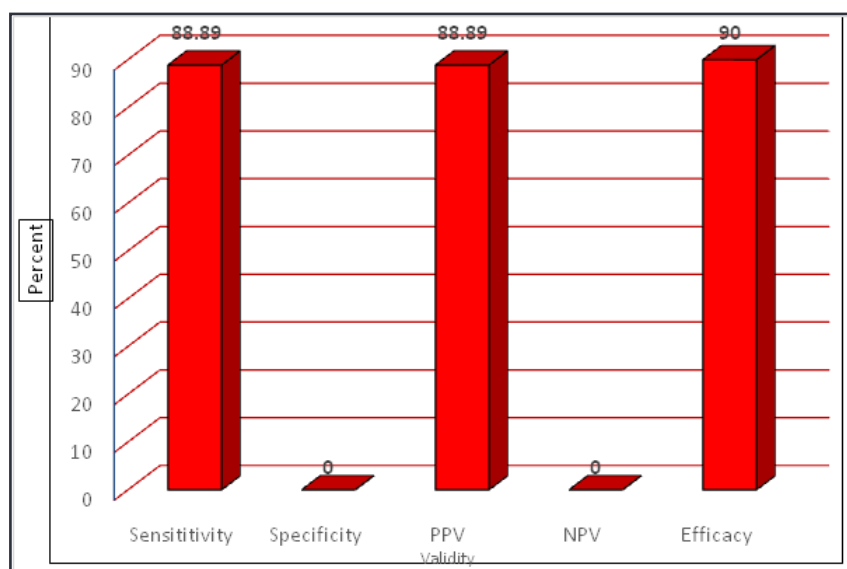
Ultrasound imaging has been found to be useful in imaging various structures of oral and maxillofacial region. As there is a paucity of data regarding the use of ultrasound for diagnosis of periapical lesions of endodontic origin, a need was felt to conduct a study to evaluate the diagnostic validity of this imaging modality and to compare its diagnostic capability with conventional radiography.<sup>[7]</sup>

Traditionally, the size of a periapical radiolucent lesion has been thought to give an indication as to the nature of

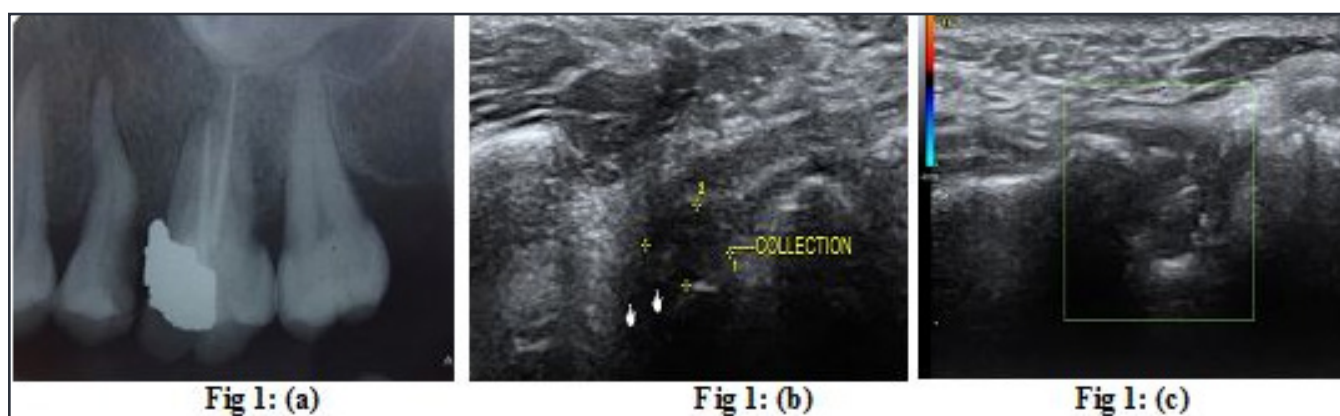
**Table 1: Correlation of ultrasonography with histopathological features.**

Type of Lesion	Ultrasonographic Features	Histopathologic Features	Correlation
Abscess	4	4	4(100%)
Granuloma	9	7	7(77.7%)
Cyst	7	9	7(77.7%)
<b>Total</b>	<b>20</b>	<b>20</b>	<b>18(90%)</b>

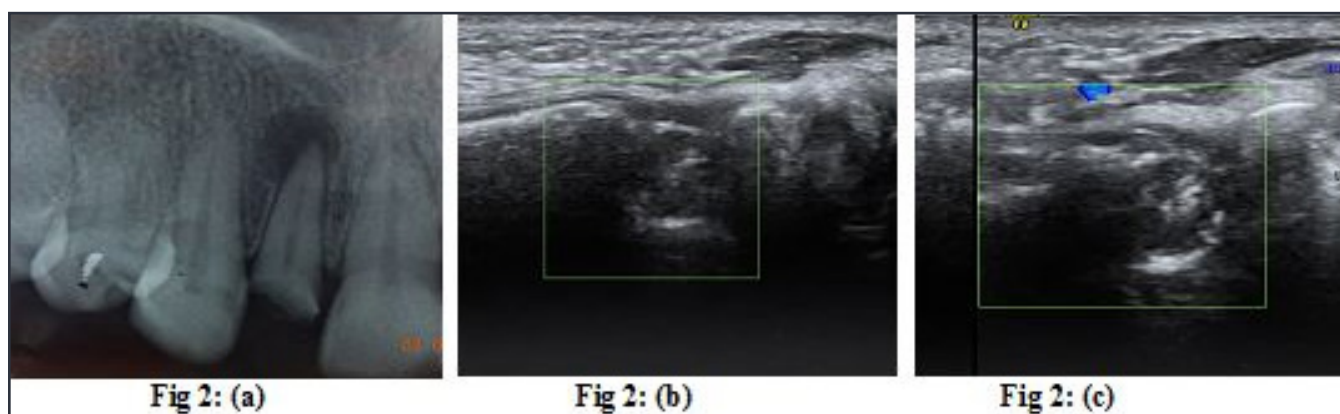**Graph 1: Correlation of Ultrasonography with histopathological features.****Graph 2: Correlation between ultrasonography and radiographic features**



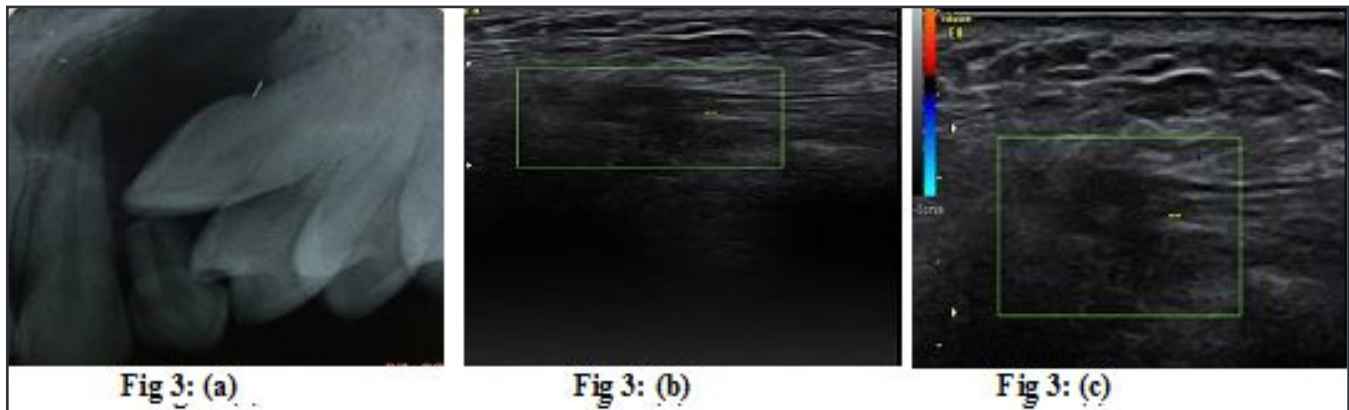
**Graph 3: Diagnostic validity of ultrasonography.**



**Fig. 1: (a)** Intraoral periapical radiograph showing ill-defined radiolucency at the apex of root of premolar tooth. **(b)** Hypo echoic and anechoic regions, with mixed echogenic patterns and numerous scattered internal echoes. **(c)** US image showing vascularity in some areas on color Doppler examination.



**Fig. 2: (a)** Conventional radiograph image showing well circumscribed periapical radiolucency with sclerotic border suggestive of periapical granuloma. **(b)** US image showing poorly defined hypo echoic area. **(c)** US image reveals vascular supply on color Doppler examination suggestive of periapical granuloma.



**Figure 3: (a) Conventional radiograph image showing well circumscribed periapical radiolucency with sclerotic border suggestive of periapical cyst. (b) US images reveal a hypo echoic well contoured cavity surrounded by reinforced bone walls. (c) No evidence of internal vascularization on color Doppler Examination**

the underlying disease process.<sup>[7]</sup> On the other hand, using ultrasound, the observers were able to accurately identify the underlying disease process reasonably accurately, even though the size measurements obtained in three dimensions using the ultrasound software were not reliable.

Ultrasound is a coherent, mechanical vibration. It propagates as a sequence of compression and rarefaction waves which are transmitted by virtue of the elastic forces between adjacent tissue particles. At the interface between two tissues with different acoustic impedance, the ultrasound waves undergo refraction and reflection. The echo is the part of the ultrasound wave reflected back toward the crystal. The ultrasonic image is an electronic representation of data generated from returning echoes and displayed on a TV monitor. Each returning echo generates one bit of data and many bits together form the electronic image. Moving the transducer probe by hand over the area of interest changes the sector plane and thus a real time three-dimensional impression of the space is obtained.<sup>[8, 9]</sup>

A qualitative comparison of the echo intensity with that of normal tissue aids in the interpretation of gray values on an image. An interface or area of tissue area with low echo intensity is termed “hypo echoic” or “transonic”; an area where no reflection of echoes occurs is termed “anechoic” and an area which has high echo intensity is termed “hyper echoic”. Nonhomogeneous areas which have different types of tissues demonstrate a “dishomogenous echo”, consisting of hyper echoic and hypo echoic signals. Bony surfaces demonstrate total reflection of echoes (hyper echoic/totally echogenic).<sup>[9]</sup> The application of colour doppler mode provides additional information regarding the presence, direction, and velocity of blood flow within the examined tissue.

In this study, it was possible to obtain sonographic images in all the 20 cases and to evaluate the content and measure the size of the lesion and its vascularization. This finding was in accordance with studies by Cotti et al. and Gundappa et al.

Of the 20 cases studied, ultrasound could detect periapical abscess in 4 cases, periapical granulomas in 9 cases and periapical cysts in all 7 cases. But there were 4 cases of periapical abscess 7 periapical granulomas and 9 periapical cysts which were confirmed histopathologically. Two of the periapical cysts were misdiagnosed as periapical granuloma may be due thick cortical bone or secondary infection. Sonography has definite advantages over conventional imaging modalities as it is non-invasive, less costly, lacks radiation hazards, availability of images in digital form and achievement of maximum patient compliance. Drawbacks of sonography include the need for expert operator in interpreting the findings and inter observer variations may be present. Diagnostic validity of sonography is diminished in areas where there is thick overlying bone.<sup>[10]</sup> Conventional radiography provides preliminary information about the lesion; it represents the anatomic location and provides information about the size of the lesion. It enables the diagnosis of the periapical disease, but not its nature. Ultrasound imaging is possible through thinned or perforated cortical bone. It can provide accurate information on the pathological nature of periapical disease.

## Conclusion

The results of this study demonstrated that ultrasound imaging has the potential to be used for the evaluation of periapical lesions and have diagnostic accuracy of 90 percent as compared to conventional radiography



in identifying and differentiating periapical lesions of endodontic origin. However, further studies are required to establish a definite correlation.

### Acknowledgements

I extend my sincere and heartfelt gratitude to H.O.D, Dr. Srisha Basappa. I express my sincere gratitude to other faculties who have contributed for the study.

### References

1. Cotti E, Campisi G, Giraud V, Puddu G. A new technique for the study of periapical bone lesions: ultrasound real time imaging. *Int Endodont J* 2002; 35:148-152.
2. Mouyen F, Benz C, Sonabend E, Lodter J. Presentation and physical evaluation of RadioVisioGraphy. *Oral Surg Oral Med Oral Pathol* 1989; 68: 238–242.
3. Sullivan JE, Di Fiore PM, Koerber A. RadioVisioGraphy in the detection of periapical lesions. *J Endod* 2000; 26: 32–35.
4. Cotti E, Vargiu P, Dettori C, Mallarini G. Computerized tomography in the management and follow-up of extensive periapical lesion. *Endod Dent Traumatol* 1999; 15: 186–189.
5. Geibel MA, Schreiber ES, Bracher AK, Hell E, Ulrici J, Sailer LK, Ozpeynirci Y, Rasche V <https://www.thieme-connect.com/products/ejournals/pdf/10.1055/s-0034-1385808>.
6. Cotti E, Campisi G, Ambu R, Dettori C. Ultrasound real time imaging in differential diagnosis of periapical lesions. *Int Endod J* 2003; 36:556–563.
7. Christo Naveen Prince, Chandrakala Shekarappa Annapurna, S. Sivaraj, and I. M. Ali. Ultrasound imaging in the diagnosis of periapical lesions. *Journal of Pharmacy and Bioallied Sciences* 2012; 4(2): p369–p372
8. M Gundappa, SY Ng\* and EJ Whaites Comparison of ultrasound, digital and conventional radiography in differentiating periapical lesions. *Dentomaxillofacial Radiology* 2006; 35:326–333.
9. Lalit Chandra Boruah, AC Bhuyan. Ultrasonography and Colour Doppler as a Diagnostic Aid in Differentiation of Periapical lesions of Endodontic Origin: Report of Two Cases. *World Journal of Dentistry*, July-September 2010; 1(2):117-119.
10. Rajendran N, Sundaresan B. Efficacy of ultrasound and colour power Doppler as a monitoring tool in the healing of endodontic periapical lesions. *J Endod* 2007; 33:181-86.

#### \*Corresponding author:

**Dr Smitha J D**, Postgraduate student, Department of Oral Medicine and Radiology, Farooqia Dental College and Hospital, Mysuru, Karnataka, India.

**Phone:** +91 9481926624

**Email:** drupadgiri19@gmail.com

**Financial or other Competing Interests:** None.